

Seroprevalence of Microsporidiosis in Immunocompromised Patients in Kano-Nigeria

I Omalu, D Duhlińska, G Anyanwu, V Pam, P Inyama

Citation

I Omalu, D Duhlińska, G Anyanwu, V Pam, P Inyama. *Seroprevalence of Microsporidiosis in Immunocompromised Patients in Kano-Nigeria*. The Internet Journal of Parasitic Diseases. 2006 Volume 1 Number 2.

Abstract

Microsporidial infections have been recognized as an increasingly important infection in immunocompromised patients, particularly those infected with HIV/AIDS.

Stool samples were examined for microsporidial spores by modified Giemsa staining technique and IgG antibodies to Microsporidia in Sera samples were detected by ELISA. Faecal examination showed that 14/192 (7.29%) of HIV/AIDS patients had microsporidia, comprising - Enterocytozoon bienewsi 8/14 (57.14%), Encephalitozoon intestinalis 5/14(35.71%) and mixed infection of both 1/14(7.14%), while 0/50 of HIV-negative patients had microsporidia. The difference between them was not significant (X^2 , $p>0.05$). Enterocytozoon

bienewsi was detected in 3/23(13.04%) and 3/35(8.57%) of TB/HIV/AIDS and TB/HIV-negative patients.

Serological evaluation showed that 22/168(13.10%) of HIV/AIDS and 2/60 (3.33%) of HIV-negative patients were seropositive.

There was a significant difference (X^2 , $p<0.05$) in their infection rates. 0/30 of TB patients were seropositive.

There was a significant association ($p<0.05$) between patients with Microsporidia and CD4 lymphocytes counts of ≤ 50 cells/ μ l and also with diarrhoea.

Detection of Microsporidia in Immunocompromised patients has not been described previously in this area.

INTRODUCTION

Since the advent of HIV infection with its profound and progressive effect on the cellular immune system, a group of human opportunistic pathogens has come into prominence, namely the microsporidia. Microsporidia are widespread, small obligate intracellular protozoan parasites which are transmitted via resistant spores.¹ Many genera of the family microsporida were known to be pathogens of invertebrates and vertebrates hosts.² Their role in human disease was not appreciated until the AIDS pandemic.

Two microsporidia Enterocytozoon bienewsi and Encephalitozoon intestinalis have been identified as possible causes of diarrhoeal illness in HIV-infected patients.^{3, 4} Of the several species that infect man Enterocytozoon bienewsi were the first documented case and the most commonly recognized microsporidia that causes gastrointestinal disease in immunocompromised patient particularly in HIV/AIDS. This parasite is commonly observed in HIV-infected patients with CD4 Lymphocytes counts of less than 50 cells/mm³ who complain of chronic diarrhoea, nausea, malabsorption and severe weight loss.^{1, 5} Whereas Encephalitozoon intestinalis causes both a disseminated and intestinal

infections frequently associated with nephritis, sinusitis or bronchitis.⁶ Based on recent data it is now known that some domestic and wild animals may be naturally infected with the following microsporidian species: Encephalitozoon cuniculi, Encephalitozoon intestinalis, Enterocytozoon bienewsi.⁷ Cases of intestinal Microsporidiosis have been detected in HIV-seronegative asymptomatic individuals, and organ transplant recipients.^{8, 9} This study aimed at providing baseline information on the status of Microsporidiosis in Kano.

METHODS

Study populations were in and out patients of Infectious Disease Hospital (IDH) Kano state. Each patient had a standardized clinical evaluation and provided a fresh stool specimen upon admission.

For microsporidial investigation, faecal (0.5g) specimen was homogenized in distilled water in ratio 1:8. After filtration in a 300 μ m pore mesh sieve and centrifuged at 1500rpm, smears were prepared from sediments, fixed in methanol and stained with 10% Giemsa solution¹⁰ and examined at x1000 magnification (oil emersion). Giemsa stained spores were

broadly oval, with the cytoplasm staining light grey-blue with a dark stained nucleus Spores were classified as either small about 1.0 – 1.6 x 0.7 – 1.0µm (*Ent. bienewisi*) or large about 2.0 – 2.5 x 1.0 – 1.6µm (*E. intestinalis*).

For serological evaluation an Indirect Enzyme Linked Immunosorbent assay ELISA technique was carried out with washed whole spores of microsporidia. Micro-ELISA plates were coated with 10⁵ microsporidial spores as antigens; test and control sera were diluted in 1:2000. ¹¹T-lymphocytes were counted with a CD4 cell kit, and clinical evaluations were done physically and by oral examination.

RESULTS

Prevalence of microsporidia in stool samples of immunocompromised patients is shown in Table 1. In HIV/AIDS Patients 14(7.29%) of the 192 patients examine had microsporidia, comprising- *Enterocytozoon bienewisi* 8 /14 (57.14%), *Encephalitozoon intestinalis* 5/14 (35.71%) and mixed infection of both 1/14 (7.17%), while none of the HIV-negative patients had microsporidia. The rate of infection was not significant (X², p>0.05) between them. *Enterocytozoon bienewisi* was detected in 3(13.04%) of the 23 TB patients with HIV/AIDS as against a parasite rate of 3(8.57%) recorded among 35TB patients without HIV – infection. IgG antibodies to microsporidia were detected in 22(13.10%) of the 168 HIV/AIDS and 2(3.33%) of the 60 HIV-negative patients sera screened. There was a significant difference (X², p<0.05) in their infection rates. In the TB patients none were found to be seropositive out of 30 screened (Table 2).

Six (100%) HIV/AIDS patients had CD4 lymphocytes counts of < 50 cells/µl while 5(25.00%) had CD4 lymphocytes counts of > 50 cells /µl. their difference was very significant (X², p<0.05). Only 1(100 %) TB/HIV/AIDS patient with microsporidia had a CD4 lymphocyte count of < 50 cell/µl(Table 3).

In HIV/AIDS patients 34(43.59%) had diarrhoea, 21(26.29%) had abdominal pain, 19(24.36%) had both diarrhoea and abdominal pain, while 4(5.03%) showed no clinical symptoms.

Figure 1

Table 1: Prevalence of intestinal Microsporidia in Stool Samples of Immuno-compromised Patients in Kano

Overall	Microsporidial species Encountered							
			<i>Ent. bienewisi</i>		<i>E. intestinalis</i>		<i>E. intestinalis</i>	
Stool samples	No.	No.+ve (%)	No.+v (%)	No.+v (%)	No.+v (%)	No.+ve (%)	No.+ve (%)	
	Exam.	*	e	e	e			
HIV-ve Patients	50	0	0.00	0	0.00	0	0.00	0
HIV/AIDS Patients	192	14	7.29	8	57.1	5	35.7	1
TB/HIV/AIDS Patients	23	3	13.0	3	13.0	0	0.00	0
TB/HIV-ve Patients	35	3	8.57	3	8.57	0	0.00	0
Total	300	20	6.67	14	4.67	5	1.67	1

*+ve- Positive

Table 2: Prevalence of Anti-Microsporidial Antibodies in Sera of Immunocompromised patients in Kano

	HIV-Negative Patients		Immunocompromised Patients	
	No.	(%)	No.	(%)
			HIV/AIDS Patients	TB Patients
*SP+	2	3.33	22 13.10	0 0.00
*SP-	58	96.67	146 86.90	30 100
Total	60	-	168	30

*SP+ -Seropositive, SP- Seronegative

Figure 2

Table 2: Number of CD4 cells/µl of Immunocompromised patients with and without Microsporidia

	Immunocompromised patients							
	HIV-negative patients		HIV/AIDS Patients		TB/HIV/AIDS Patients		TB/HIV-ve patients	
No. of CD4 cells	No.	No.+ve*	No.	No.+ve	No.Exa	No.+v	No.Exa	No.+ve
> 50 cells/µl	3	0 (0.00)	20	5 (25.00)**	5	0(0.00)	0	0 (0.00)
< 50 cells/µl	2	0 (0.00)	6	6(100)	1	1(100)	0	0(0.00)
Total	25	-	26	-	6	-	0	-

* - No of patients with microsporidia ** - Percentage in parenthesis

Figure 3

Figure 1: Histogram showing Clinical Symptoms of Patients with Microsporidiosis

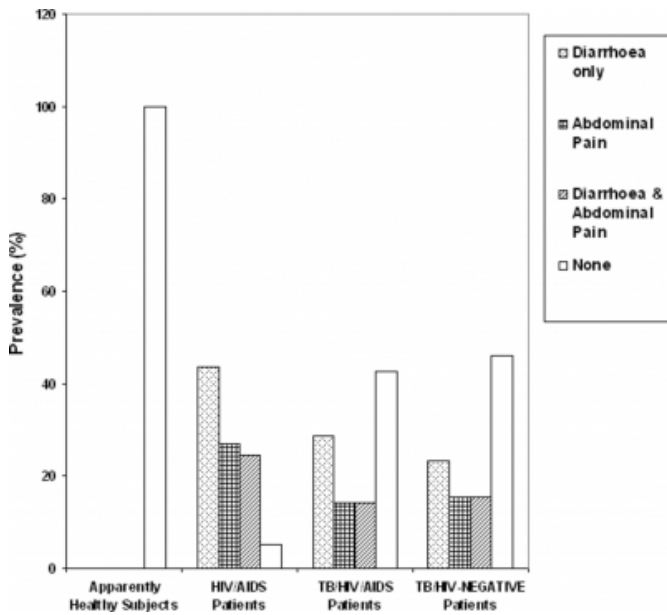
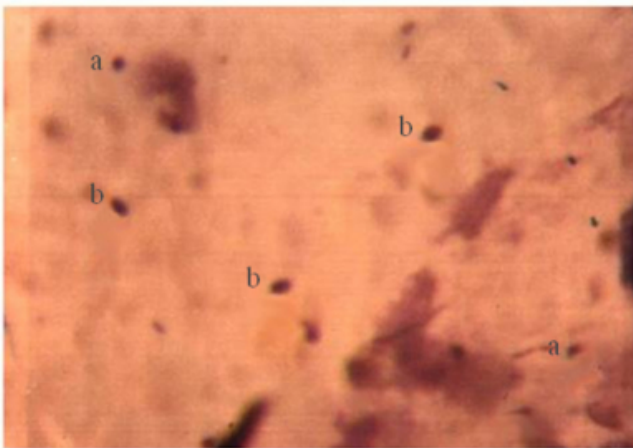


Figure 4

Plate 1: Oval spores with dark stained nucleus of (a) and (b) in faecal concentrate x 1000



In TB/HIV/AIDS patients 2(28.57%) had diarrhoea, 1(14.29%) had abdominal pain, 1(14.29%) had both abdominal pain and diarrhoea, while 3(42.86%) had none. 3(23.08%) of the TB/HIV- negative patients had diarrhoea, 2(15.38%) had abdominal pain, 2(15.38%) had both and 6(46.15%) had none (Figure 1). There was a significant association between microsporidiosis and diarrhoea. *Enterocytozoon bienersi* is the most prevalent parasite in intestinal infections (Plate 1).

DISCUSSION

This report described an emerging gastrointestinal protozoon

in Kano, where there has been little or no study. Microsporidiosis generally *Enterocytozoon bienersi* caused up to 70% of otherwise unexplained cases of chronic diarrhoea involving patients with HIV/AIDS and low CD4 lymphocytes counts, the modified Giemsa staining technique for stool provides a useful means of screening clinical specimen. The occurrence of microsporidiosis in immunocompromised patients and non immunocompetent (HIV-negative) patients conforms with earlier reports that microsporidiosis occurs in immunocompromised patients particularly in HIV/AIDS. The presence of microsporidial antibodies in sera of both HIV/AIDS and HIV-negative patients will help greatly in detecting subclinical infections.

All the patients with CD4 lymphocytes counts of < 50 cells/μl had microsporidiosis which confirmed the fact that microsporidiosis is usually observed in patients with low CD4 cells. Possible explanation of fewer patients with low CD4 cells of < 50 cells/μl is probably due to the fact that patients in developing countries like Nigeria die from other tropical disease before the CD4 cells drop to the critical level of about 50 cells or less, below which the intestinal microsporidiosis becomes clinically significant. Most of the HIV/AIDS patients had chronic diarrhoea leading to severe weight loss, this report conforms to earlier findings and this was followed by abdominal pain and both. In TB patients few had diarrhoea, which might be due to the fact that patients were already on medication as of the time of this study.

A final deduction from this study is the appreciation of the increasing prevalence of microsporidiosis and that most patients have antigens and antibody levels, indicative of subclinical infections, suggesting that this parasite could be a serious hazard to AIDS and other immunodeficient patients due to causes other than AIDS, or probably due to most tropical diseases like malaria, schistosomiasis etc., and that infection are not at present being diagnosed. Since presently there is no satisfactory treatment for microsporidial infections, there is need for making chemotherapy for microsporidial disease a priority area of research.

References

- Orenstein, J.M., Chiang, J., Steinberg, W., Smith, P.D., Rotterdam, H. and Kotler, D.P. (1990). Intestinal Microsporidiosis as a cause of diarrhoea in human immunodeficiency virus infected patients: a report of 20 cases. *Human Pathology* 21(5): 475-481.
- Canning, E.U. and Lom, J. (1986). *The Microsporidia of Vertebrates*.

- London. Academic Press, 289p.
3. Kotler, D.P.(1995). Gastrointestinal Manifestations of immunodeficiency infection. *Advance Internal Medicine* 40:197-224.
 4. Moura, A., Hirschfeld, M.P., Brazil, P., Sodre, F.C. and Palhares, M.C.A. Internaitonal Workshop on "Microsporidiosis and cryptosporidiosis in immunodeficient patients. Ceske BudeJovice, Czech republic. September 28 - October 1, 1993.
 5. Asmuth, D.M., DeGirolami, P.C., Federman, M., Ezratty, C.R., Pleiskow, D.K., Desai, G. and Wanke, C.A. (1994). Clinical features of Microsporidiosis in patients with AIDS. *Clinical Infectious Diseases* 18: 819-825.
 6. Accoceberry, I.,Desportes-Livage, I.,Achbarou, A., Biligui, S., Danis, M. and Datry, A. (1999). Production of Monoclonal Antibodies directed against the Microsporidium. *Enterocytozoon bienewsi. Journal of Clinical Microbiology* 37(12): 4107-4112.
 7. CDC. (2004). Microsporidiosis. *Parasite and Health* pp. 1 -3.
 8. Rabodonirina, M., Bertocchi. M., Desportes-Livage, L., Cotte, L., Levrey, H., Piens, M.A., Monneret, G., Celard, M., Mornek, J.F. and Mojon, M. (1996). *Enterocytozoon bienewsi* as a cause of chronic diarrhoea in heart-lung transplant recipient who was seronegative for human immunodeficiency virus. *Clinical Infectious Diseases* 23: 114-117.
 9. Sandfort, J., Hannemann, A., Stark, D., Gelderblom, H. and Ruf, B. International Workshop on "Microsporidiosis and Cryptosporidiosis in immunodeficient patients" Ceske BudeJovice Czech republic September 28 - October1, 1993.
 10. Van-Gool, T., Hollister, W.S., Eeftinck-Schaffenkerk, J., Van-Den Bergh Weerman, M.A., Terpstra, W.J., Vanketel, R.J., Reiss P. and Canning, E.U. (1990). Diagnosis of *Enterocytozoon bienewsi* Microsporidiosis in AIDS patients by recovery of spores from faces. *The Lancet* 336: 697-698.
 11. Hollister, W.S., and Canning, E.U. (1987). An Enzyme Linked Immunosorbent Assay (ELISA) for detection of antibodies to *Encephalitozoon cuniculi* and its use in determination of infections in man. *Parasitology* 94: 209-219.
 12. Marshall, M.M., Naumovitz, D., Ortega, Y. and Sterling, C. (1997). Waterborne Protozoan Pathogens. *Clinical Microbiology Review*. 10: 67- 85.
 13. Hollister, W.S., Canning, E.U; Aarons, E.J. (1995) *Encephalitozoon cuniculi* isolated from the urine of an AIDS patient, which differs from canine and Murine isolates. *Journal of Eukryotic Microbiology* 42(4): 367-372.
 14. Dascomb, K., Clark, R., Aberg, J., Pulvirenti, J., Hewitt, R.G., Kissinger, P. and Didier, E.S. (1999). Natural History of Intestinal Microsporidiosis among Patients Infected with human Immunodeficiency Virus. *Journal of Clinical Microbiology* 37(10): 3421-3422.
 15. Orenstein, J.M.(1991). Microsporidiosis in Acquired Immunodeficiency Syndrome *Journal of Parasitology* 77: 843-864.

Author Information

I.C.J. Omalu, Ph.D

Department of Zoology, University of Jos

D. D. Duhlinska, Ph.D

Department of Zoology, University of Jos

G. I. Anyanwu, Ph.D.

Department of Zoology, University of Jos

V. A. Pam, MSc

National Veterinary Research Institute Vom

P. U. Inyama, MSc

Department of Zoology, University of Jos