

**Publisher** : John Wiley & Sons, Inc.  
**Location** : Hoboken, NJ, USA  
**ISBN (print-13)** : 9781394189731  
**Title (main)** : Elements of Reproduction and Reproductive Diseases of Goats  
**Copyright (publisher)** : © 2024 John Wiley & Sons, Inc.  
**Numbering (edition)** : First  
  
**Creators (editor)** : **Tanmoy Rana**

**Affiliation** : Department of Veterinary Clinical Complex, West Bengal  
University of Animal and Fishery Sciences, West Bengal, India, India

**Subject Info** :  
Veterinary Medicine - Farm Animals  
  
Veterinary Internal Medicine  
  
Veterinary Microbiology, Parasitology, Infectious Diseases & Immun

**ID (unit)** : c20  
**ID (file)** : c20  
**Count (pageTotal)** : 10  
**Event (xmlCreated)** : 2024-02-05 (SPi Global)  
**Numbering (main)** : 20  
**Numbering (pageFirst)** : 1  
**Numbering (pageLast)** : 10

20

## Diseases of the Scrotum

**Felix Uchenna Samuel**<sup>1,2</sup>, **Mojetoluwa S. Afolabi**<sup>2</sup>, **Adeniyi Njideka**<sup>2</sup>, **Ogunkunle Nathaniel**<sup>2</sup>, **Kolawole Jonathan Bamidele**<sup>3</sup>, **Hycinth Ndabatsado Kolo**<sup>4</sup>

<sup>1</sup> Faculty of Veterinary Medicine, National Animal Production Research Institute, Ahmadu Bello University, Zaria, Nigeria

<sup>2</sup> Department of Food and Animal Science, Alabama A&M University, Normal, USA

<sup>3</sup> Faculty of Veterinary Medicine, Ahmadu Bello University, Zaria, Nigeria

<sup>4</sup> Department of Animal Health and Production, Federal University of Technology, Minna, Nigeria

## Abstract

Diseases of the scrotum in goats represent a critical aspect of their health and reproductive well-being. This chapter provides a concise overview of these diseases, encompassing their causes, symptoms, and management. Scrotal diseases in goats can arise from bacterial infections, parasitic infestations, trauma, and environmental factors. Common conditions include caseous lymphadenitis, caused by *Corynebacterium pseudotuberculosis*, and parasitic infestations like sarcoptic mange. Recognizable symptoms encompass scrotal swelling, abnormal discharges, itching, altered behavior, and changes in reproductive activity. Effective management necessitates maintaining hygiene, quarantine and testing for new animals, vaccination, parasite control, and timely treatment. Prioritizing these measures aids in safeguarding the scrotal health of goats, ensuring their optimal reproductive capacity and overall vitality.

**Keywords:** disease; goat; buck; scrotum; reproduction

---

### 20.1 Introduction

The scrotum or scrotal sac is an external male reproductive structure located at the base of the penis that consists of a suspended dual-chambered sac of skin and smooth muscle. It is present in most terrestrial male mammals. The scrotum contains the external spermatic fascia, testes, epididymis, and ductus deferens. It is a distention of the perineum and carries some abdominal tissues into its cavity, including the testicular artery, testicular vein, and pampiniform plexus. The perineal raphe is a small, vertical, slightly raised ridge of scrotal skin under which is found the scrotal septum. It appears as a thin longitudinal line that runs front to back over the entire scrotum. The scrotum is biologically homologous to the labia majora in female animals. It is absent in fusiform marine mammals, such as whales and seals, as well as in some lineages of land mammals, such as the afrotherians, xenarthrans, and numerous families of bats, rodents, and insectivores (Singh et al. 2019).

The scrotum regulates the temperature of the testes and maintains it at two or three degrees below the core body temperature. Higher temperatures affect spermatogenesis. Temperature control is accomplished by the smooth muscles of the scrotum moving the testicles either closer to or further away from the abdomen dependent upon the ambient temperature. This is accomplished by the cremaster muscle in the abdomen and the dartos fascia (muscular tissue under the skin).

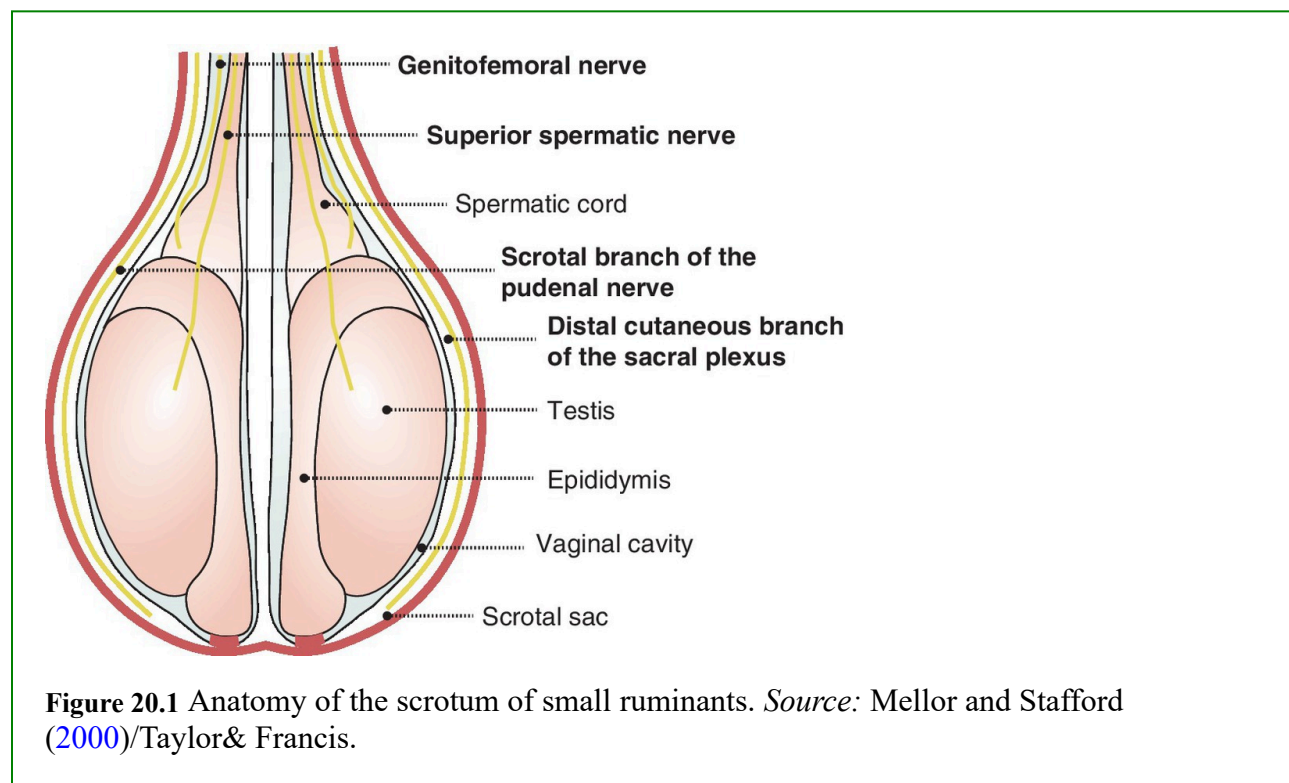
The scrotal skin is thin, has few hair follicles and little or no subcutaneous fat, and is richly supplied with sweat glands. Warm arterial blood is cooled as it passes next to venous blood within the pampiniform plexus. Seminiferous tubule temperature needs to be 2–3 °C lower than the body temperature for viable production of spermatozoa (Chaurasia et al. 2023).

The situation of the scrotum and testicles outside the abdominal cavity may provide additional

advantages. The external scrotum is not affected by abdominal pressure. This may prevent the emptying of the testes before the sperm have matured sufficiently for fertilization. Another advantage is that it protects the testes from jolts and compressions associated with an active lifestyle. Animals that move at a steady pace – such as elephants, whales, and marsupial moles – have internal testes and no scrotum. Unlike placental mammals, some male marsupials have a scrotum that is anterior to the penis, which is not homologous to the scrotum of placental mammals, although there are several marsupial species without an external scrotum. In humans, the scrotum may provide some friction during intercourse, helping to enhance the activity (Perumal et al. 2023).

## 20.2 Structure and Anatomy

The external layer of the scrotum is made of skin which is usually darker in color than the neighboring areas of skin. Underneath the skin is the dartos muscle, or tunica dartos. The tunica dartos helps to regulate the temperature of the testicles by contracting to reduce the surface area of the scrotum and decrease heat loss, or relaxing to increase the surface area of the scrotum to help with cooling (Sultan et al. 2023) (Figure 20.1).



Another muscle inside the scrotum is the cremaster muscle. There are two such muscles, one on each side. Each of the muscles covers the testes and the spermatic cord and reaches into the pelvis through the inguinal canal. The function of the cremaster muscles is to raise or lower the testicles. This further helps to maintain the testicles at an appropriate temperature (Mohamed et al. 2023).

The cremasteric reflex is a response to light stroking of the inner thigh. It causes the muscle to

contract and the testes to elevate. It is also possible for some men to contract the cremaster muscles voluntarily.

The spermatic cord provides blood supply to the testes, vas deferens, and cremaster muscle. It also contains nerves and lymph vessels which connect to the internal structures of the scrotum.

The scrotal septum divides the scrotum into two chambers. It is an extension of the perineal raphe, a line of tissue that extends from the anus through the perineum and upwards through the midline of the penis (Abah et al. 2023).

### 20.2.1 Anatomy

The scrotum is one of the vital accessory male reproductive organs which is formed by a suspended sac of skin and smooth muscle that has two chambers. It is present in most terrestrial (earthly) males, located under the penis. It is a protective reservoir for the testis and related anatomical structures. Asymmetry of the testis is explicit in that one testis is typically lower than the other, the function of which is to avoid compression in the event of an impact (Husnurrizal et al. 2023).

The perineal raphe is a landmark – a small, vertical, slightly raised ridge of scrotal skin marking the scrotal septum. It is a thin longitudinal line which runs from front to back over the entire scrotum. The contents of the scrotum on the external spermatic fascia, testes, epididymis, and ductus deferens. It is a distention of the perineum, and carries some abdominal tissues such as testicular artery, testicular vein, and pampiniform plexus. The scrotum becomes covered with pubic hair at puberty, a secondary sex character. It is biologically homologous to the labia majora in females (Mansour et al. 2023).

- *Nerve supply*: the scrotal surface is divided into the anterolateral portion, supplied by the genital branch of the genitofemoral nerve, anterior portion supplied by the anterior scrotal nerves, a branch of the ilioinguinal nerve, posterior portion supplied by the posterior scrotal nerve, a branch of the perineal nerve, while its inferior surface is supplied by perineal branches of the posterior femoral cutaneous nerve (Husnurrizal et al. 2023).
- *Blood supply*: the blood vessels of the scrotum are the anterior and posterior scrotal artery, and the testicular vein.
- *Integument*: the scrotal integument is relatively thin and has an underlying fascia, the tunica dartos. It is composed of skin-associated tissues, namely hair, sebaceous glands, apocrine sweat glands, and smooth muscles. The skin on the scrotum is pigmented compared to the rest of the body. The septum is a connective tissue membrane dividing the scrotum into two cavities (Mansour et al. 2023).
- *Lymphatic system*: this is formed by lymphatic vessels, namely the superficial inguinal lymph nodes, superficial subinguinal glands, and the deep subinguinal glands.
- *Physiology*: the scrotum regulates the temperature of the testes, and maintains them at 35 °C/95 °F, which is two degrees below the normal body temperature of 37 °C/98.6 °F.

Higher temperatures may affect spermatogenesis. Temperature control is accomplished by the smooth muscles of the scrotum moving the testicles either closer to or further away from the abdomen dependent upon the ambient temperature, which is accomplished by the cremaster muscle in the abdomen and the dartos fascia. Furthermore, their situation outside the abdominal cavity provides additional advantage(s) that scrotum is unaffected by abdominal pressure, which may prevent the emptying of the testes before the sperm are matured sufficiently for fertilization. It also protects the testes from jolts and compressions (Mansour et al. [2023](#)).

## 20.2.2 Anatomical Variations

There are a number of possible anatomical variations of the scrotum. In general, these variations are quite rare (Thobela et al. [2023](#)).

- *Accessory scrotum*: an extra scrotum that develops, usually further down the perineum, toward the anus. The accessory scrotum does not contain testes. It does not generally cause problems with the primary scrotum.
- *Bifid scrotum*: this is when there is a cleft in the middle of the scrotum. It occurs when there is not enough testosterone early in development for the scrotum to fuse. Bifid scrotum often occurs alongside hypospadias.
- *Ectopic scrotum*: where the normal scrotum is located in a different location.
- *Penoscrotal transposition*: where the penis and the scrotum are located incorrectly with respect to each other. The penis can be below the scrotum (complete transposition) or in the middle of the scrotum (partial transposition.)

## 20.3 Diseases of the Scrotum of Bucks

### 20.3.1 Orchitis

Orchitis is an inflammatory condition that affects the testicles, which are part of the male reproductive system. In goats, as in other animals, orchitis can be a serious health issue that can lead to discomfort, pain, and potential fertility problems. The following reference provides a more detailed overview of orchitis in goats (Foster [2023](#)).

#### 20.3.1.1 Causes of Orchitis in Goats

##### 20.3.1.1.1 Infections

Orchitis is often caused by bacterial, viral, or fungal infections. In goats, common infectious causes include the following.

- *Bacterial infections*: pathogenic bacteria such as *Brucella melitensis*, which causes brucellosis, can lead to orchitis.
- *Viral infections*: the caprine arthritis encephalitis (CAE) virus, a retrovirus, can also cause orchitis in goats. CAE primarily affects the joints and nervous system but can lead to other complications, including testicular inflammation.
- *Fungal infections*: fungal pathogens can occasionally cause orchitis, especially in environments where fungi thrive.

#### 20.3.1.1.2 Trauma

Physical injury or trauma to the scrotal area can result in inflammation and orchitis.

#### 20.3.1.2 Symptoms of Orchitis

The signs and symptoms of orchitis in goats may include swelling of the scrotum and testicles, pain and discomfort leading to difficulty walking or standing, reluctance to move or lie down, general signs of illness such as fever and loss of appetite, reduced activity and playfulness, changes in the texture and appearance of the scrotal skin, and possible discharge from the penis.

#### 20.3.1.3 Diagnosis

Diagnosing orchitis involves a thorough physical examination, history taking, and diagnostic tests. These tests may include blood tests to identify infectious agents or markers of inflammation, ultrasound or other imaging techniques to assess the extent of inflammation and damage, and testicular biopsy in severe cases to determine the cause and extent of damage.

#### 20.3.1.4 Treatment

Treatment of orchitis depends on the underlying cause. It often involves administering antibiotics or antiviral medications to address infections, providing pain relief and anti-inflammatory drugs to alleviate discomfort and swelling, supportive care, such as ensuring proper nutrition and maintaining a clean and comfortable environment.

#### 20.3.1.5 Prevention

Preventing orchitis involves implementing good management practices: maintaining a clean and hygienic environment for goats to minimize the risk of infections, isolating new animals before introducing them to the herd to prevent the spread of potential pathogens, and implementing a vaccination program, where appropriate, to protect against infectious diseases such as brucellosis and CAE (Foster 2023).

### 20.3.2 Epididymitis

Epididymitis is the inflammation of the epididymis, a coiled tube located on the surface of the

testicle. The epididymis plays a crucial role in the maturation and storage of sperm. Epididymitis can occur due to various factors, including infections, trauma, and other underlying conditions. The following reference provides a detailed overview of epididymitis in goats (Monteiro et al. 2023).

### 20.3.2.1 Causes of Epididymitis in Goats

#### 20.3.2.1.1 Infections

Bacterial, viral, or fungal infections can lead to epididymitis. Common infectious causes include the following.

- *Bacterial infections*: bacteria such as *Brucella melitensis*, which causes brucellosis, can result in epididymitis. Other pathogenic bacteria may also be involved.
- *Viral infections*: the CAE virus, while primarily associated with arthritis and neurological symptoms, can occasionally lead to epididymitis.
- *Fungal infections*: fungi can also infect the epididymis and cause inflammation.
- *Ascending infection*: in some cases, infections may ascend from the urinary tract to the epididymis.

#### 20.3.2.1.2 Trauma

Physical injury or trauma to the scrotal area can lead to epididymitis.

#### 20.3.2.1.3 Other Causes

Conditions such as testicular torsion (twisting of the testicle and spermatic cord) or certain systemic illnesses can indirectly lead to epididymitis.

### 20.3.2.2 Symptoms of Epididymitis

The signs and symptoms of epididymitis in goats may include swelling and inflammation of the epididymis, leading to a lump or enlargement of the scrotum, pain and discomfort, causing the goat to be restless and exhibit signs of distress, reluctance to walk, stand, or lie down comfortably, changes in behavior, including decreased activity and appetite, possible discharge from the penis, and fever and other signs of illness.

### 20.3.2.3 Diagnosis and Treatment

Diagnosing epididymitis involves a combination of clinical examination, history, and diagnostic tests, which may include palpation of the scrotum and epididymis to assess swelling and tenderness, blood tests to identify markers of infection and inflammation

ultrasound or other imaging techniques to visualize the epididymis and testicles, aspiration of fluid from the epididymis for laboratory analysis.

Treatment of epididymitis depends on the underlying cause and may include antibiotics or antiviral medications to address the specific infectious agent, pain relief and antiinflammatory drugs to alleviate discomfort and swelling, and supportive care, including rest, proper nutrition, and a clean environment,

### 20.3.3 Hydrocele

A hydrocele is a build-up of fluid within the scrotum, leading to swelling. It can occur due to trauma, infection, or other underlying conditions. While not typically a serious condition, a large hydrocele may cause discomfort and affect the goat's movement. While hydroceles are more commonly associated with humans, they can also occur in animals, including goats (Balara et al. 2022).

#### 20.3.3.1 Causes of Hydrocele in Goats

- *Trauma*: physical injury or trauma to the scrotal area can disrupt the blood vessels and lymphatic vessels, leading to the accumulation of fluid.
- *Inflammation or infection*: inflammatory conditions or infections affecting the scrotum or testicles can trigger an abnormal accumulation of fluid.
- *Congenital factors*: some cases of hydrocele in goats may be congenital, meaning they are present at birth due to developmental abnormalities.
- *Lymphatic obstruction*: obstruction or dysfunction of the lymphatic vessels, which play a role in fluid drainage, can result in fluid accumulation.

#### 20.3.3.2 Symptoms of Hydrocele

Hydroceles in goats are characterized by swelling and enlargement of the scrotum, which may vary in size, a fluid-filled, soft, and sometimes fluctuant mass within the scrotum and discomfort or mild pain, which may lead to changes in the goat's behavior or gait.

#### 20.3.3.3 Diagnosis

Diagnosing hydrocele involves a veterinarian's evaluation, which may include palpation and physical examination of the scrotum to assess the size, consistency, and fluid content, and aspiration of fluid from the scrotum for laboratory analysis. In some cases, small hydroceles may resolve on their own without treatment. However, larger or persistent hydroceles may require intervention.

#### 20.3.3.4 Treatment

- *Aspiration*: if the hydrocele is causing discomfort or hindering the goat's movement, the



veterinarian may aspirate (draw out) the fluid using a needle and syringe. This is typically a temporary solution as the fluid may reaccumulate.

- *Surgery*: surgical intervention may be considered for larger or recurrent hydroceles. The procedure involves draining the fluid and addressing the underlying cause, such as repairing any damaged blood vessels or lymphatic vessels.

### 20.3.3.5 Prevention

Hydroceles are often a result of underlying causes such as trauma or infections. Preventive measures include providing a safe and clean environment for goats to minimize the risk of trauma, and implementing good hygiene practices to prevent infections in the scrotal area. It is important to note that the scrotal region is sensitive and important for the goat's reproductive health. If you suspect a hydrocele or notice any changes in your goat's scrotum, it is crucial to consult a veterinarian. Only a veterinarian can accurately diagnose the condition and recommend appropriate treatment options based on the goat's specific situation.

### 20.3.4 Scrotal Dermatitis

Scrotal dermatitis, also known as “scrotal dermatosis” or “scrotal eczema,” refers to skin inflammation and irritation of the scrotum. This can be caused by various factors such as allergies, parasites, fungal or bacterial infections, or physical irritation. It may manifest as redness, itching, hair loss, and scaling of the skin. Scrotal dermatitis can have various causes, and managing the condition typically involves identifying and addressing the underlying factors (Struthers et al. [2022](#)).

#### 20.3.4.1 Causes of Scrotal Dermatitis in Goats

- *Allergies*: contact with allergens, such as certain plants, chemicals, or materials, can lead to an allergic reaction on the scrotal skin.
- *Parasites*: infestations of mites, lice, or other external parasites can cause irritation and inflammation on the scrotum.
- *Fungal infections*: fungal pathogens, such as dermatophytes, can infect the scrotal skin and result in dermatitis.
- *Bacterial infections*: bacterial infections, whether primary or secondary to other skin issues, can contribute to scrotal dermatitis.
- *Environmental factors*: excessive moisture, humidity, and poor hygiene in the scrotal area can create a favorable environment for skin irritation and infections.
- *Trauma*: physical irritation or injury to the scrotal skin can lead to inflammation and dermatitis.

#### 20.3.4.2 Symptoms of Scrotal Dermatitis

Scrotal dermatitis in goats may present with redness, swelling, and inflammation of the scrotal skin, itching and discomfort, leading to scratching or rubbing of the area, formation of lesions, sores, or scabs on the scrotum, hair loss and changes in the texture of the skin and restlessness, irritability, and attempts to alleviate discomfort by licking or biting the scrotum.

#### 20.3.4.3 Diagnosis and Treatment

Diagnosing scrotal dermatitis involves a veterinarian's examination, which may include visual inspection of the scrotal area to assess the extent of inflammation and skin changes and skin scrapings or swabs to identify potential parasites, fungi, or bacteria.

Treatment of scrotal dermatitis depends on the underlying cause and may include the following.

- *Topical treatments*: application of medicated creams, ointments, or sprays to address inflammation, infections, or parasites.
- *Antibiotics or antifungals*: prescription of oral medications to combat bacterial or fungal infections, if present.
- *Pain relief and antiinflammatories*: administration of medications to alleviate discomfort and reduce inflammation.
- *Hygiene and management*: implementing proper hygiene practices, keeping the scrotal area clean and dry, and providing a comfortable environment.

#### 20.3.4.4 Prevention

Maintain a clean and dry living environment to minimize moisture-related issues. Regularly inspect goats for signs of skin irritation or parasites, provide proper grooming and hygiene care for the animals, and avoid exposure to potential allergens or irritants.

#### 20.3.5 Scrotal Hernia

A scrotal hernia occurs when a part of the abdominal contents (intestines, fat, etc.) protrudes into the scrotum through a weakened area or defect in the abdominal wall. This can cause a visible bulge and may lead to complications if not addressed. Scrotal hernias can occur in both humans and animals, including goats. This condition can be serious and may require surgical intervention to correct (Kitessa et al. [2022](#)).

##### 20.3.5.1 Causes of Scrotal Hernia in Goats

Scrotal hernias in goats can have different underlying causes.

- *Congenital*: some scrotal hernias are present at birth and occur due to a failure of the abdominal muscles to close properly during fetal development.
- *Trauma*: injuries or trauma to the abdominal wall can weaken the muscles and create openings through which abdominal contents can protrude.

### 20.3.5.2 Symptoms of Scrotal Hernia

Symptoms of scrotal hernia in goats may include visible swelling or bulge in the scrotum, often containing abdominal tissue, difficulty walking or moving due to discomfort or pain, behavioral changes such as restlessness or lethargy, and possible complications if the hernia becomes incarcerated (unable to be pushed back in) or strangulated (blood supply to the herniated tissue is compromised).

### 20.3.5.3 Diagnosis and Treatment

Diagnosing scrotal hernia typically involves a veterinarian's examination, which may include physical inspection and palpation of the scrotum and hernia site to assess the size, location, and content of the hernia, ultrasound or other imaging techniques to evaluate the extent of the hernia and its impact on surrounding structures.

Treatment of scrotal hernia often involves surgical correction, especially if the hernia is large, causing discomfort, or at risk of complications. The surgical procedure aims to reposition the herniated contents back into the abdominal cavity, repair and strengthen the weakened abdominal wall to prevent recurrence, and close any openings through which the hernia protruded.

### 20.3.5.4 Prevention

Preventing scrotal hernias in goats involves avoiding excessive physical stress or trauma that could weaken the abdominal muscles. If hereditary factors are suspected, selecting breeding animals without a history of hernias may help reduce the risk of passing on this condition.

## 20.3.6 Tumors

Tumors can also develop in the scrotum, such as testicular tumors. While less common, these growths can affect the health of the goat and may require surgical intervention. Tumors in goats, as in any living organisms, are abnormal growths of cells that can develop in various parts of the body. Tumors can be benign (noncancerous) or malignant (cancerous). They can arise from different types of tissues and can have a range of effects on the goat's health (Muñoz-Salinas et al. [2022](#)).

### 20.3.6.1 Types of Tumors

- *Benign tumors*: these tumors do not spread to other parts of the body and are generally

less aggressive. Examples of benign tumors that can occur in goats include lipomas (fatty tumors), fibromas (connective tissue tumors), and papillomas (wart-like growths).

- *Malignant tumors*: these tumors are cancerous and can invade nearby tissues and potentially spread to other parts of the body through a process called metastasis. Examples of malignant tumors in goats include mast cell tumors, lymphomas, and certain types of sarcomas.

### 20.3.6.2 Causes and Risk Factors

The exact causes of tumors in goats are often complex and can involve genetic, environmental, and other factors. Some risk factors that might contribute to the development of tumors include the following.

- *Genetic predisposition*: certain breeds or genetic lines may be more prone to specific types of tumors.
- *Exposure to carcinogens*: environmental factors such as exposure to chemicals, radiation, or infectious agents could increase the risk of tumor development.
- *Age*: older goats may have a higher likelihood of developing tumors.

### 20.3.6.3 Symptoms

The symptoms of tumors in goats can vary widely depending on the type, location, and size of the tumor. Common signs might include swelling or lump under the skin or in internal organs, changes in behavior or activity level, weight loss and decreased appetite and difficulty breathing, swallowing, or moving, depending on the tumor's location.

### 20.3.6.4 Diagnosis and Treatment

Diagnosing tumors in goats involves a veterinarian's evaluation, which may include physical examination and palpation of the goat's body to locate and assess tumors, imaging tests such as ultrasound, X-rays, or CT scans to visualize the tumor's size and location, and

biopsy, which involves removing a small piece of the tumor for laboratory analysis to determine if it is benign or malignant.

Treatment options for tumors in goats depend on factors such as the tumor type, size, and location.

- *Surgical removal*: benign tumors are often removed surgically if they are causing discomfort or impeding the goat's normal function.
- *Chemotherapy or radiation*: for certain malignant tumors, chemotherapy or radiation

therapy might be considered to target and reduce the growth of cancer cells.

- *Supportive care*: managing pain, maintaining proper nutrition, and providing a comfortable environment to support the goat's overall well-being.

### 20.3.6.5 Prevention

Preventing tumors in goats involves maintaining good herd health practices, which includes proper nutrition, minimizing exposure to potential carcinogens, and regular veterinary care. Additionally, selective breeding and genetic management can play a role in reducing the risk of certain hereditary tumor predispositions.

### 20.3.7 Trauma

Trauma refers to any physical injury that the goat may experience, whether due to accidents, fights, falls, or other external factors.

#### 20.3.7.1 Scrotal Trauma in Goats

Scrotal trauma specifically involves injuries to the scrotal region, which includes the testicles and surrounding tissues. This can occur in various ways, such as kicks, blows, or accidents that impact the scrotal area. Scrotal trauma can result in the following outcomes.

- *Swelling*: trauma can lead to immediate swelling of the scrotum due to blood pooling or fluid accumulation in the affected area.
- *Bruising*: the force of the impact can cause blood vessels to rupture, leading to bruising (discoloration) of the scrotal skin.
- *Pain*: the goat may experience pain and discomfort due to the injury, leading to behavioral changes such as restlessness, avoidance of movement, or vocalization.
- *Reduced fertility*: severe scrotal trauma can potentially impact the health of the testicles and sperm production, leading to temporary or permanent fertility issues.

### 20.3.8 Parasitic Infections

Parasites, such as mites or lice, can infest the scrotal skin and cause irritation and inflammation. Parasitic infestations can lead to discomfort, skin problems, and other health issues.

#### 20.3.8.1 Types of Parasites

- *Mites*: mites are tiny arthropods that can infest the skin of goats. They may cause

conditions like mange, characterized by intense itching, hair loss, and inflammation. Scabies mites, for instance, can burrow into the skin and cause severe itching and discomfort.

- *Lice*: lice are wingless insects that feed on the goat's blood and can attach to the skin and hair. They cause itching, hair loss, and skin irritation. There are two main types of lice that affect goats: biting lice and sucking lice.

### 20.3.8.2 Symptoms of Parasitic Infestations

- *Intense scratching*: goats infested with mites or lice will often scratch, rub, or bite at the affected areas in an attempt to alleviate itching.
- *Hair loss*: infestations can lead to patchy hair loss and thinning of the coat.
- *Skin irritation*: affected skin may appear red, inflamed, or scaly.
- *Restlessness*: infested goats may be restless and display abnormal behavior due to the discomfort.
- *Reduced production*: parasitic infestations can affect the overall health of goats, leading to decreased milk production and weight gain.

### 20.3.8.3 Diagnosis and Treatment

Diagnosing parasitic infestations typically involves a veterinarian's examination, which may include the following.

- *Visual inspection*: a thorough visual examination of the goat's skin and hair to look for signs of parasites or skin irritation.
- *Skin scraping*: a small sample of skin may be scraped and examined under a microscope to identify the presence of mites or lice.

Treatment for parasitic infestations involves the following factors.

- *Topical treatments*: medicated shampoos, sprays, or powders can be used to kill and remove parasites from the skin.
- *Injectable medications*: some parasiticides can be administered through injections.
- *Environmental management*: cleaning and disinfecting the goat's living area can help reduce the risk of reinfestation.

- *Supportive care*: providing proper nutrition, hydration, and comfort can support the goat's recovery.

#### 20.3.8.4 Prevention

Preventing parasitic infestations involves good herd management practices.

- *Regular inspections*: regularly inspect goats for signs of parasites, especially in areas like the scrotum.
- *Quarantine*: quarantine new animals before introducing them to the herd to prevent the spread of parasites.
- *Parasite control*: implement a parasite control program that includes strategic deworming and rotating classes of dewormers to prevent resistance.
- *Hygiene*: maintain a clean and dry living environment to discourage parasites.

#### 20.3.9 Heat Stress

While not a disease, extreme heat can lead to scrotal edema (swelling) due to increased blood flow to the area. This can affect sperm production and fertility (Abioja et al. [2022](#)).

##### 20.3.9.1 Scrotal Edema and Fertility

One of the effects of heat stress in male goats is scrotal edema, which is swelling of the scrotum due to increased blood flow to the area. Scrotal edema can lead to discomfort and affect the goat's fertility. The testicles are sensitive to temperature changes, and excessive heat can lead to decreased sperm production and impaired sperm quality. This can result in reduced fertility and lower breeding success rates.

##### 20.3.9.2 Other Effects of Heat Stress

- *Dehydration*: high temperatures can cause goats to become dehydrated, leading to reduced feed intake, weight loss, and electrolyte imbalances.
- *Respiratory distress*: goats may pant excessively to cool down, leading to respiratory distress and an increased risk of respiratory infections.
- *Reduced milk production*: heat-stressed dairy goats may experience reduced milk production and altered milk composition.
- *Decreased immune function*: heat stress can weaken the immune system, making goats more susceptible to infections and diseases.

### 20.3.9.3 Prevention and Management

- *Shade*: provide adequate shade and shelter to protect goats from direct sunlight.
- *Water*: ensure access to clean and cool drinking water at all times.
- *Ventilation*: provide good ventilation in barns and shelters to promote air circulation.
- *Cooling methods*: use fans, misters, or sprinklers to help cool the goats and their environment.
- *Time of feeding*: feed goats during the cooler parts of the day to minimize heat generation from digestion.
- *Reduce stress*: minimize handling, transport, and other stressful activities during hot weather.
- *Breeding*: consider breeding practices that take into account heat stress, such as avoiding breeding during the hottest months.

## 20.4 Conclusion

Diseases of the scrotum in goats pose significant challenges to their reproductive health and overall well-being. By understanding the causes, symptoms, and management strategies for scrotal diseases, goat farmers and livestock managers can take proactive measures to prevent and control these issues. Through proper hygiene, regular health monitoring, and timely veterinary care, goats can lead healthier lives, contributing to the sustainability and success of the livestock industry.

## References

- Abah, K.O., Fontbonne, A., Partyka, A., and Nizanski, W. (2023). Effect of male age on semen quality in domestic animals: potential for advanced functional and translational research? *Veterinary Research Communications* **47**: 1125–1137.
- Abioja, M.O., Logunleko, M.O., Majekodunmi, B.C. et al. (2022). Roles of candidate genes in the adaptation of goats to heat stress: a review. *Small Ruminant Research* **218**: 106878.
- Balaro, M.F.A., Cosentino, I.O., Ribeiro, A.C.S., and Brandão, F.Z. (2022). Ultrasound diagnosis in small ruminants: occurrence and description of genital pathologies. *Veterinary Sciences* **9** (11): 599.
- Chaurasia, D.K., Nahak, A.K., Mishra, P.C. et al. (2023). Studies on seasonal variation of scrotal parameters in Ganjam buck. *Pharma Innovation* **12**: 2303–2304.
- Foster, A.P. (2023). Challenges in the diagnosis and management of skin diseases in alpacas, goats, pigs, and sheep. *Journal of the American Veterinary Medical Association* **261** (S1): S86–S94.
- Husnurrizal, H., Akbar, D.G.P., Siregar, T.N. et al. (2023). Comparison of reproductive performance of Gembrong goats and male Boerka goats. *Livestock and Animal Research* **21** (1): 1–8.



- Kitessa, J.D., Merga, A.F., Afata, A.W., and Feyisa, C.T. (2022). Inguinal herniorrhaphy in goat: the novel way of using vest-over-pants closure technique. *Veterinary Record Case Reports* **10** (2): e321.
- Mansour, M., Wilhite, R., Rowe, J., and Hafiz, S. (ed.) (2023). *Guide to Ruminant Anatomy: Dissection and Clinical Aspects*. Hoboken, NJ: Wiley.
- Mellor, D.J. and Stafford, K.J. (2000). Acute castration and/or tailing distress and its alleviation in lambs. *New Zealand Veterinary Journal* **48** (2): 33–43.
- Mohamed, R.H., Mohamed, R.S., Abd El-Hamid, I.S. et al. (2023). Semen quality, testicular characteristic, biochemical profile and histopathology of testes of goats under heat stress conditions. *Assiut Veterinary Medical Journal* **69** (176): 76–87.
- Monteiro, M.M., de Mello Seal, D.C., de Souza, J.H. et al. (2023). Effect of antifreeze protein type III on frozen/thawed of spermatozoa recover from goat epididymis. *Research in Veterinary Science* **154**: 108–112.
- Muñoz-Salinas, F., Andrade-Montemayor, H.M., De la Torre-Carbot, K. et al. (2022). Comparative analysis of the protein composition of goat milk from French Alpine, Nubian, and Creole breeds and Holstein Friesian cow milk: implications for early infant nutrition. *Animals* **12** (17): 2236.
- Perumal, P., Sunder, J., De, A.K. et al. (2023). Flaxseed oil modulates testicular biometrics, hormone, libido, antioxidant and semen profiles in endangered Teressa goat of Andaman and Nicobar Islands. *Reproductive Biology* **23** (1): 100730.
- Singh, M., Kaswan, S., Cheema, R.S. et al. (2019). Effect of scrotal bifurcation on breeding soundness traits in Beetal bucks during summer season. *Tropical Animal Health and Production* **51**: 1585–1590.
- Struthers, J.D., Chako, C., Ruppert, S. et al. (2022). Diagnostic challenge in veterinary pathology: alopecic crusting dermatitis in a goat. *Veterinary Pathology* **59** (2): 182–185.
- Sultan, K.H., Ahmad, W.K., and Mohamed, A.R. (2023). Effect of buck's body weight on some reproductive parameters and it's relation with sexual behavior. *Iraqi Journal of Veterinary Sciences* **37** (3): 733–737.
- Thobela, L.T., Mohlabeng, I.M., and Selala, L.J. (2023). Phenotypic relationship between body weight, body condition score and testicular measurement traits in dorper rams raised in Syferkuil farm, Limpopo Province, South Africa. *Pakistan Journal of Zoology* **55** (1): 457.