

# Antiplasmodial Activity and Toxicological Profile of Alkaloids Obtained from *Securideca longipedunculata*

\*<sup>1</sup>Sulaiman, S.R., <sup>2</sup>Jigam, A.A., <sup>2</sup>Abubakar, A., <sup>2</sup>Salau, B.R. and <sup>3</sup>Taylor, D.

<sup>1</sup>Department of Biochemistry, Ibrahim Badamasi Babangida University, Lapai, Nigeria

<sup>2</sup>Department of Biochemistry, Federal University of Technology, Minna, Nigeria

<sup>3</sup>Division of Pharmacology, University of Cape Town, Cape Town, South Africa

Received: May 8, 2019;

Final revision: July 18, 2019;

Accepted: July 23, 2019

## Abstract

Malaria is a public health problem that has reduced societal productivity particularly arising from resistance to common orthodox drugs. We hypothesized that the available diverse plant resources in Nigeria can be used to resolve the problem of resistance. *Securideca longipedunculata* is a medicinal herb, used locally in the treatment of malaria. Fifteen albino mice were grouped in five and administered 100, 200 and 400 mg/kg bw, while the last two groups represent the negative and positive controls. Twenty four Wistar rat were grouped into two for toxicological analysis. The test group was administered 200 mg/kg bw of the extract on alternate days while the control group was given normal saline for 4 weeks. Blood parameters were monitored on a weekly basis, with the liver, kidney, heart and spleen harvested for histopathology. The extract had both *in vitro* and *in vivo* antiplasmodial activity of IC<sub>50</sub> of 4.65 µg/ml and 1216 parasite/µl. In the toxicity studies, RBC count and PCV continuously decreased compared to the control, while urea and bilirubin concentrations were significantly (p<0.05) higher than the control, indicative of damage to the RBC, kidney and liver. Similarly, serum ALT and AST activities were significantly (p<0.05) higher compared to the control, also indicative of liver damage and hemolysis. However, there was no significant (p<0.05) change in the white blood cell indices. Histopathological analysis revealed leucocyte infiltration, vascular congestion and inflammation in the kidney and liver. Thus, the extract had adverse effect on RBC count, kidney and liver, although could serve as a potential target for malaria if bioassay guided fractionation is further carried out to differentiate between the toxic and the antiplasmodial agents.

**Keywords:** Parasite, Urea, Haemoglobin, Inflammation, Histopathology

## 1.0 Introduction

Malaria is a parasitic disease caused by a protozoan belonging to the phylum Plasmodium [1] which is being transmitted by over 70 species of anopheles mosquitoes. Malaria is caused by any of the five protozoa namely *Plasmodium malariae*, *Plasmodium ovale*, *Plasmodium vivax*, *Plasmodium falciparum* and *Plasmodium knowlesi*, but *P. falciparum* is the most virulent specie [2]. Malaria is a common health challenge in developing world with sub-Saharan Africa most susceptible to the disease [3], representing about 95% of global malaria burden. In 2016, there was an estimated 216 million cases of malaria, an increase of about 5 million cases over 2015. Death reached 445,000, a similar number to the previous year. The global response to malaria is at a crossroads, after an unprecedented period of success in malaria control [4]. The targets by World Health Organization (WHO) Global Technical Strategy for Malaria (2016-2030) calling for a 40% reduction in malaria case incidence and death rates by 2020 is not visible [5]. A dramatic recrudescence of malaria is ongoing, due to the increasing resistance of vector to insecticides and resistance of parasites, mainly *Plasmodium falciparum* to the commonly available drugs such as chloroquine, artemisinin and sulphadoxine-pyrimethamine [6].

---

\*Corresponding Author: Tel: +234(0)8065863683, E-mail: rukkysule82@gmail.com

© 2019 Faculty of Natural and Applied Sciences, Al-Hikmah University, Nigeria; All rights reserved

The use of medicinal plants for the treatment of parasitic diseases is well known and documented since ancient times. Several compounds isolated from nature also form a rich source of diverse structures for optimization to obtain improved therapeutics [7]. Alkaloids, one of such compounds, are physiologically active nitrogenous base secondary metabolites found in plants, fungi, bacteria and marine organisms [8]. Literature search revealed that a host of antiplasmodial alkaloids have been derived from African flora, ranging from indole alkaloids, amides, cryptolepines and many yet to be identified [9]. The use of such compounds as antiplasmodial agents can only be enhanced when empirical evidences exist for their efficacy and toxicity profile. They could also be used as a template for the synthesis of more active, less toxic drug derivatives because drug efficacy, pharmacology and toxicity are important parameters in the selection of compounds for development.

*Securideca longipedunculata* is commonly known as the violet plant. It is a medicinal herb, grown in Savanna belonging to the family Polygalaceae. The roots are taken orally either powdered or as infusions for treating chest complaints, headache, inflammation, malaria, tuberculosis, infertility problems, venereal diseases, constipation, urethral discharges, dysentery, rheumatism, fibroditis, toothache, cough, snake bite and wound dressing [10]. *S. longipedunculata* has been reported to have several pharmacological activities which include antioxidant [11], anti-inflammatory [12], antifungal [13] and antiparasitic [14]. This research was carried out to evaluate antiplasmodial potentials and toxicological profile of crude alkaloids extracted from *S. longipedunculata* root bark in animal model.

## 2.0 Materials and Methods

### 2.1 Parasite

Chloroquine sensitive *Plasmodium berghei* strain (NK65) was obtained from National Institute of Medical Research (NIMR), Lagos, Nigeria and was maintained in the laboratory by serial passage.

### 2.2 Animals

Healthy Swiss albino mice of either sex, weighing between 15-19 g and Wistar rats of either sex weighing 170-200 g were obtained from Department of Pharmacy, Ahmadu Bello University, Zaria, Nigeria. The animals were acclimatized for 2 weeks, prior to the experiments and comfortably housed in a plastic cage under standard environmental conditions, with free access to commercial feed pellets and water *ad libitum*. The experiments were conducted in strict compliance with internationally accepted principles for laboratory animals' use and care as contained in the Canadian Council on Animal Care Guidelines and Protocol Review [15].

### 2.3 Collection and Identification of Plant Material

Fresh roots of *S. longipedunculata* were collected from Sonfada Gabi Area in Bida Local Government Area of Niger State, Nigeria. Taxonomic identification and authentication of the plant was done at National Institute for Pharmaceutical Research and Development (NIPRD), Idu, Abuja, where voucher specimen (NIPRD/H/6755) was deposited. The root sample was washed under running tap water to free it from soil particles, after which the bark was removed and air dried at room temperature.

### 2.4 Extraction of Alkaloid Rich Extract

Alkaloids were extracted using the methods Yubin *et al.* [16]. Briefly, the method involved moistening 500 g of pulverized root bark with 150 ml of 0.5 M calcium carbonate in order to render it alkaline and also to remove the phenolic content. The mixture was air dried and free alkaloids were extracted under reflux using petroleum ether at 40°C for 2 h. The filtrate was concentrated to one third of its volume and mixed thoroughly with equal volume of dilute 2 M sulphuric acid in a separating funnel. The aqueous part contains the alkaloidal salts while the organic fraction contains pigments, fat and weak bases. The aqueous fraction was treated with diethyl ether to obtain crude alkaloids [16].

### 2.5 Acute Toxicity Testing

Acute toxicity was determined using Lorke's method as modified by Chinedu *et al.* [17]. This method involved three stages, with the outcome from each stage determining the next step. In the first stage, 16 albino mice were divided into 4 groups of 4 animals each. The different doses (50, 200, 400 and 800 mg/kg bw) of the extract were administered to the different groups. The animals were observed for 1 h post-administration and then 10 minutes every 2 h interval for 24 h. The behavioral signs of toxicity and mortality were recorded. The second stage involved the use of 12 mice, divided into 3 groups (1000, 1500 and 2000 mg/kg bw) of 4 animals each. The animals were administered with the different doses and observed for 1 h after administration and periodically for 24 h as stated above. Behavioral signs of toxicity and mortality were noted as well. The testing procedure in the third stage involved administration of 3000 mg/kg bw to 4 mice. Mortality of the mice occurred within few minutes and higher doses were not tested further. LD<sub>50</sub> was obtained by adding the highest dose of the extract that gave no mortality and the lowest dose that gave mortality divided by 2 [17].

### 2.6 In vitro Antiplasmodial Activity Testing

*In vitro* antiplasmodial activity against strains of *Plasmodium falciparum* was evaluated using the method of Singh and Rosenthal [18] against a chloroquine (CQ) sensitive strain. The extract was weighed and made to 20 mg/mL in dimethylsulfoxide (DMSO) then diluted to a start concentration of 10 µg/mL (10,000 ng/mL) for the assay. Control compound chloroquine (10.94 nM) was within the normal range for the CQ-sensitive isolate *P. falciparum* NF54 (>10 nM each). The compound was incubated together with *P. falciparum* for 72 h at 37°C. The assay was carried out in triplicate and the IC<sub>50</sub> was calculated [18].

### 2.7 In vivo Antiplasmodial Activity Testing

A 4 day curative test according to Fidock *et al.* [19] was used for the evaluation of *in vivo* antiplasmodial activity. Mice (n=15) weighing between 14-19 g were divided into five groups of three mice each. Animals in Group I-III were orally administered 100, 200 and 400 mg/kg bw of the extract respectively. Group IV was administered with 0.1 ml physiological saline, served as negative control while Group V received 10 mg/kg bw (on the first day of treatment) and 5 mg/kg bw (subsequent days) of chloroquine, served as positive control [19].

### 2.8 Toxicological Analysis

Wistar rats (n=24) were divided into 2 groups of 12 animals each. The first group comprised animals administered with 200 mg/kg bw of *S. longipedunculata* crude alkaloid extracts while the second group served as the control and the animals were given 0.1 ml physiological saline. All the treatments were done through oral administration on alternate days for four weeks. Three animals from each group were selected weekly and sacrificed. Blood samples were collected into heparinized bottles (for haematological analysis) and unheparinized bottles (for serum preparation). Selected organs namely liver, kidney, spleen and heart were harvested and fixed in 10% formalin for histopathological analysis. Serum analyses were carried out for alkaline phosphatase, alanine and aspartate aminotransferases, urea, creatinine and bilirubin using commercial kits (Randox). Hematological analyses including white blood cell (WBC) count, red blood cell (RBC) count, hemoglobin (Hb) hematocrit (PCV) and red blood cell distribution width (RBWC) were carried out with the aid of automated hematological analyser (Abacus 380-Diatron). Sections of the organ were prepared and stained with hematoxylin and eosin (H&E) and examined microscopically [20].

### 2.9 Statistical Analysis

All analysis were subjected to statistical analysis using ANOVA, with Statistical Package MINITAB version 14. A value of p<0.05 was considered as statistically significant.

## 3.0 Results

### 3.1 Percentage Yield and Acute Toxicity

The sample had a percentage yield of 8.54 % and LD<sub>50</sub> of 2500 mg/kg bw. Mortality occurred at 3000 mg/kg bw and testing did not proceed to higher doses.

### 3.2 Antiplasmodial Activity

The extract showed moderate *in vitro* activity with IC<sub>50</sub> of 4.65 µg/ml for the crude preparation. Figure 1 shows the *in vivo* antiplasmodial activity of *S. longipedunculata* root. The *in vivo* antiplasmodial activity of *S. longipedunculata* was dose dependent, because as the doses increased there was an increase in parasite clearance from the blood, although the mice that were treated with higher dose had lesser mean survival time. Table 1 represent the percentage parasite inhibition at day 14 and mean survival period of mice treated with different doses of *S. longipedunculata*.

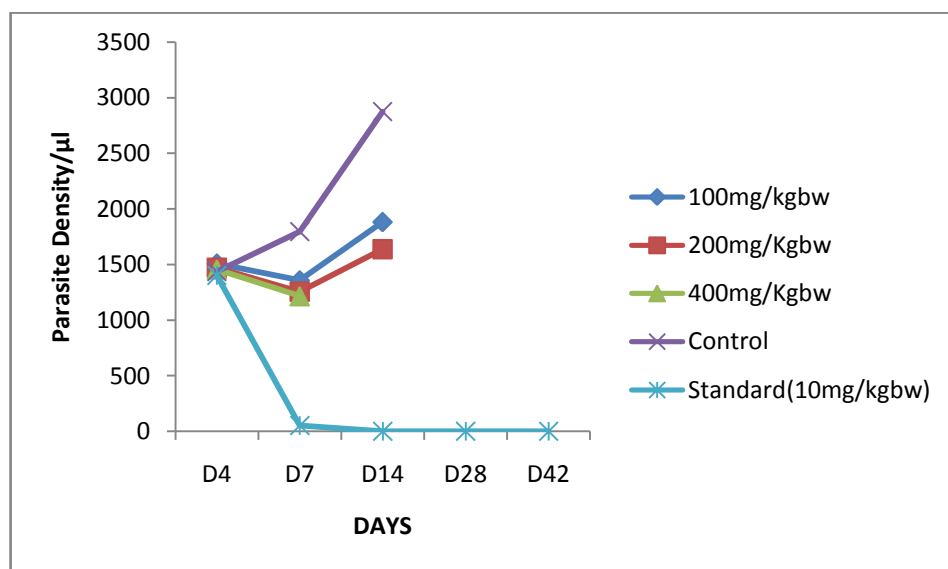


Figure1: *In vivo* antiplasmodial activity of crude alkaloid extract of *S. longipedunculata* root

Table 1: Percentage Inhibition at Day 14 and Mean Survival Period of Infected Mice

Treatments	Parasite Count	% Inhibition	Mean Survival Time
<i>S. longipedunculata</i> (100 mg/kg bw)	1881	34.53	21.33±0.67
<i>S. longipedunculata</i> (200 mg/kg bw)	1638	42.99	19.33±0.33
<i>S. longipedunculata</i> (400 mg/kg bw)	-		8.33±0.33
Physiological Saline	2873	0	16.33±0.33
Chloroquine	0	100%	56.33±3.67

### 3.3 Serum Biochemical Indices

The changes in serum biochemical parameters in the control and treated animals over the 4-week experimental period are presented in Table 2. There was no significant difference in ALP activity and creatinine concentration of treated animals compared to the control. ALT activity and urea concentrations of the animals treated with the extract increased significantly in the second and third weeks compared to the control while the activity of AST in the treated animals increased significantly in comparison to the control from the first week to the third week. A significant increase was also recorded for bilirubin concentration in the treated animals in the first week compared the control animals.

**Table 2: Serum Biochemical Parameters in Rats Administered *S. longipedunculata* Crude Alkaloid Extract**

Parameters	Control Group				Treated Group		
	Week 1	Week 2	Week 3	Week 4	Week 1	Week 2	Week 3
ALP (U/l)	162.20±2.82 <sup>a</sup>	162.35±3.77 <sup>a</sup>	148.21±11.66 <sup>a</sup>	133.30±8.62 <sup>a</sup>	141.20±9.56 <sup>a</sup>	153.90±5.72 <sup>a</sup>	212.20±8.16 <sup>a</sup>
ALT (U/l)	9.68±0.86 <sup>a</sup>	7.66±0.80 <sup>a</sup>	8.28±0.87 <sup>a</sup>	10.70±0.84 <sup>a</sup>	11.45±0.19 <sup>a</sup>	15.18±1.30 <sup>b</sup>	14.28±0.54 <sup>b</sup>
AST (U/l)	10.73±0.74 <sup>a</sup>	8.28±0.87 <sup>a</sup>	10.21±0.45 <sup>a</sup>	9.16±0.76 <sup>a</sup>	19.00±2.84 <sup>b</sup>	14.28±0.54 <sup>b</sup>	22.93±1.7 <sup>b</sup>
Urea (mmol/l)	5.37 ±0.43 <sup>a</sup>	7.30±0.18 <sup>a</sup>	5.54±0.54 <sup>a</sup>	6.74±0.63 <sup>a</sup>	3.90 ±0.29 <sup>a</sup>	9.70 ±0.55 <sup>b</sup>	10.01±0.34 <sup>b</sup>
Creatinine (mg/dl)	0.79±0.14 <sup>a</sup>	0.93±0.15 <sup>a</sup>	0.83±0.16 <sup>ab</sup>	0.79±0.11 <sup>a</sup>	0.87 ±0.02 <sup>a</sup>	1.07±0.10 <sup>ab</sup>	1.15±0.05 <sup>ab</sup>
Bilirubin (mg/dl)	0.88±0.10 <sup>ab</sup>	0.73±0.08 <sup>a</sup>	0.81±0.11 <sup>ab</sup>	0.96±0.09 <sup>a</sup>	1.26±0.28 <sup>b</sup>	0.73±0.03 <sup>a</sup>	1.15±0.32 <sup>ab</sup>

Key: ALP=Alkaline phosphatase; ALT=Alanine aminotransferase; AST=Aspartate aminotransferase. Values with the same superscripts along the row for the same week are not statistically different, while values with different superscripts along the row are statistically different.

### 3.4 Haematological Parameters

The results of hematological parameters of rats administered with *S. longipedunculata* crude alkaloids extract are presented in Table 3. The WBC count of animals treated with the extract was significantly higher compared to the control by the end of third week. In contrast, no significant difference was observed in the red cell distribution width, percentage lymphocytes, monocytes and granulocytes of the treated animals compared to the control. Likewise, there was no significant difference in red blood distribution width of the two groups.

**Table 3: Hematological parameters of rats administered with *S. longipedunculata* crude alkaloids extract**

Parameters	Control Group				Treatment Group		
	Week1	Week2	Week3	Week4	Week1	Week2	Week3
WBC (10 <sup>12</sup> /l)	12.66±4.12 <sup>a</sup>	15.49±4.97 <sup>a</sup>	12.73±1.74 <sup>ab</sup>	12.70±1.27 <sup>a</sup>	16.72±2.63 <sup>a</sup>	11.20±4.39 <sup>a</sup>	18.67±2.00 <sup>b</sup>
LYM (%)	79.96±4.50 <sup>a</sup>	72.50±4.10 <sup>a</sup>	72.96±2.69 <sup>b</sup>	85.90±2.04 <sup>a</sup>	82.56±3.78 <sup>a</sup>	70.10±5.33 <sup>a</sup>	71.37±7.43 <sup>b</sup>
GRA (%)	9.13±2.34 <sup>a</sup>	19.56±3.64 <sup>a</sup>	15.20±.47 <sup>ab</sup>	6.46±1.43 <sup>a</sup>	8.46±1.44 <sup>a</sup>	15.63±6.44 <sup>a</sup>	17.10±5.05 <sup>ab</sup>
RBC (x10 <sup>12</sup> /l)	6.65±1.92 <sup>a</sup>	9.11±0.49 <sup>b</sup>	6.66 ±0.65 <sup>b</sup>	8.58± 0.47 <sup>a</sup>	7.63±0.97 <sup>a</sup>	5.55±0.33 <sup>a</sup>	5.37±1.36 <sup>a</sup>
HGB (g/dl)	10.83±3.21 <sup>a</sup>	15.83±0.95 <sup>b</sup>	12.43±1.38 <sup>a</sup>	14.23±0.52 <sup>a</sup>	13.26±1.19 <sup>a</sup>	12.70±0.65 <sup>a</sup>	9.56± 2.39 <sup>a</sup>
HCT (%)	39.40±11.35 <sup>a</sup>	49.94±3.81 <sup>b</sup>	42.48±2.25 <sup>b</sup>	47.18±1.92 <sup>a</sup>	41.85±4.64 <sup>a</sup>	40.70±2.25 <sup>b</sup>	29.75±6.76 <sup>a</sup>
RBWC (%)	21.66±2.43 <sup>a</sup>	18.96±0.89 <sup>a</sup>	24.06±0.89 <sup>ab</sup>	21.10±0.31 <sup>a</sup>	18.86±0.22 <sup>a</sup>	19.70±1.00 <sup>a</sup>	22.96±0.43 <sup>ab</sup>

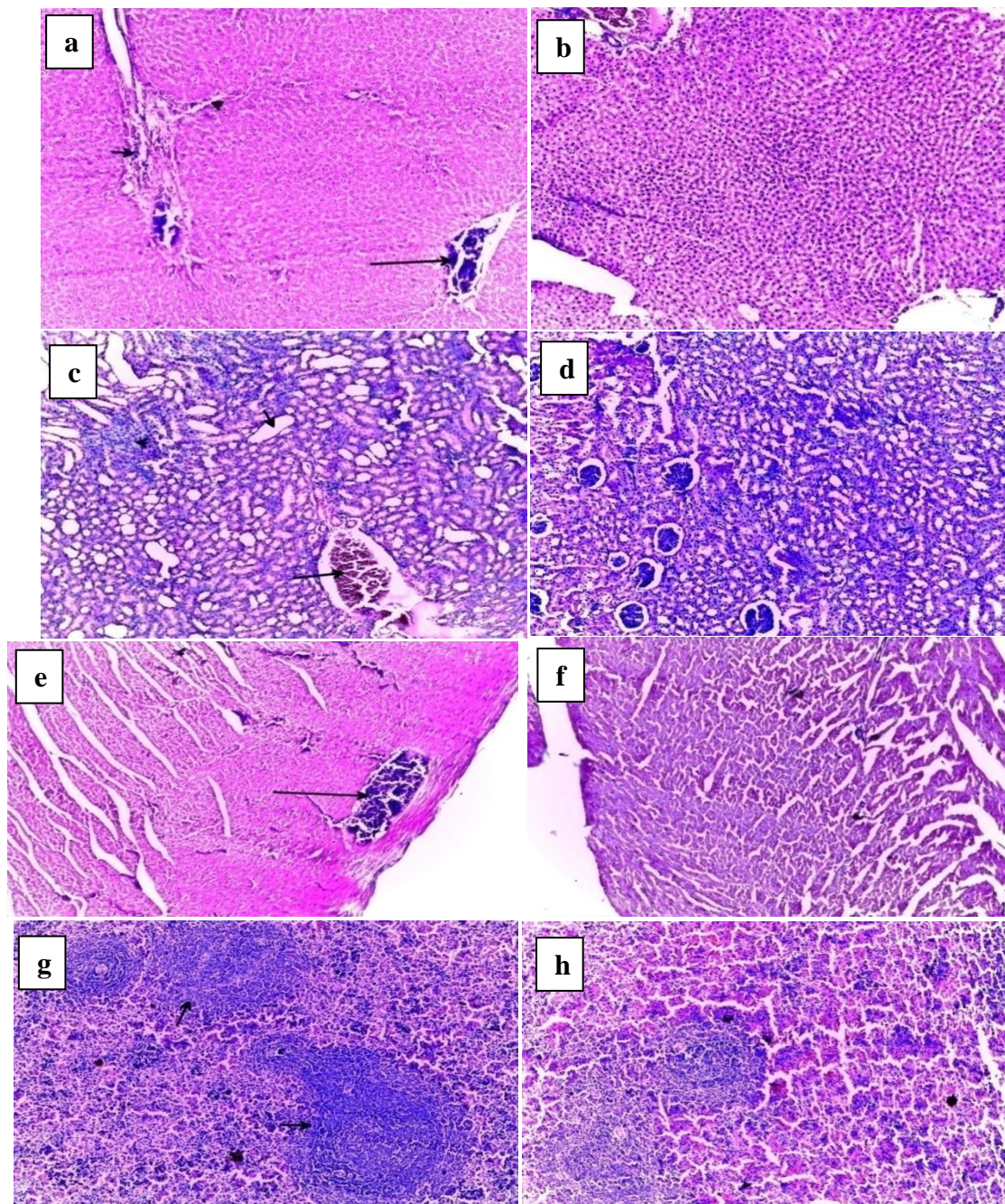
Key: WBC=White Blood Cells, LYM=Lymphocytes, GRA=Granulocytes, RBC=Red Blood Cells, HGB=Hemoglobin, HCT=Hematocrit and RBWC=Red Blood Cell Distribution Width. Values with the same superscript along the row are not statistically different, while values with different superscript along the row are statistically different.

### 3.5 Histopathological Sections of Rats Administered *S. longipedunculata*

Figure 2 represents the histological sections of liver, kidney, heart and spleen of rats treated with alkaloids rich extract of *S. longipedunculata*. Figures 2a, 2c and 2e indicate congestion in the liver, kidney and heart of treated animals.

## 4.0 Discussion

*S. longipedunculata* root alkaloids have antiplasmodial potential both *in vivo* and *in vitro*. The *in vitro* antiplasmodial activity of the crude alkaloid from this plant (IC<sub>50</sub>=4.65 µg/ml) is better than that of the leave extract (IC<sub>50</sub>=6.9 µg/ml) [21]. This may be due to variation in the quantity of phytochemicals from different parts of the plant used. In another study, Ancolio *et al.* [22] reported that IC<sub>50</sub> of the crude methanolic and chloroform root extracts is less than 250 µg/ml, suggestive of alkaloids being a more potent antiplasmodial agent compared to the crude methanolic leaf extract.



**Figure 2:** Photomicrograph of cross section of rat organs administered with *S. longipedunculata* for 4 weeks (Magnification: x100 with hematoxylin and eosin stain). (a) Section shows areas of vascular congestion, mild leucocyte infiltration in the portal areas and fibrosis in liver of rat administered 200 mg/kg bw of *S. longipedunculata*. (b) Section shows no significant pathology in liver of control rats. (c) Kidney section shows area of vascular congestion, mild inflammation and dilatation of renal tubules of rats administered 200 mg/kg bw of *S. longipedunculata*. (d) Kidney section shows no significant pathology in the control. (e) Section shows areas of vascular congestion in heart of rats administered 200 mg/kg bw of *S. longipedunculata*. (f) Heart section shows unremarkable myocardium of control rat. (g) Section shows hyperplastic lymphoid follicles in the spleen of rats administered 200 mg/kg bw of *S. longipedunculata*. (h) Section shows no significant pathology in spleen tissue of control.

The *in vivo* antiplasmodial activity of *S. longipedunculata* is comparable to that of chloroform extract of *Vernonia adoensis* at 600 mg/kg bw [23]. Although the antiplasmodial activity of *S. longipedunculata* was dose dependent, treatment at higher dose resulted in reduced survival time. This may be due to immune suppression during malaria infection coupled with the fact that the extract also stimulated red blood cell lyses. Alkaloid rich fraction of *Ricinus communis* stimulated red blood cells lyses in a concentration dependent manner [24]. Zengt *et al.* [25] also reported indole alkaloids with immunosuppressive effects.

Acute renal failure is characterized by disorders in serum levels of urea and creatinine. Increased urea and creatinine concentrations reflect the severity of renal insufficiency that occurs in association with sudden fall in glomerular filtration rate. This is because certain chemical compounds enter the proximal tubule epithelial cells and induce abnormalities in the function and metabolism of multiple intracellular membranes and organelles [26]. The crude alkaloids of *S. longipedunculata* may be nephrotoxic. Renal tubule dilation may occur from xenobiotic administration, secondary mechanism or unknown pathogenesis. Dilation may result from direct toxic injury to the tubule epithelium interfering with absorption and secretion, or it may also occur from secondary to renal ischemia or from lower urinary tract obstruction, interstitial inflammation and/or fibrosis and chronic progressive nephropathy [27]. Alanine and Aspartate aminotransferases are markers of liver damage [28]. Therefore, elevation in the activities of aminotransferases in the treated animals compared to the control also signifies liver injury.

Although WBC counts in the blood of test animals increased significantly ( $p < 0.05$ ) compared to the control in week 3, during the first two weeks there was no significant ( $p < 0.05$ ) difference in the total leucocyte counts. Chronic stress could stimulate hematopoietic stem cells in the bone marrow, increasing blood cortisol (hypercortisolemia) and reducing vagal nerve activity, leading to an accelerated synthesis of total white blood cells [29]. High WBC counts cause chronic inflammation that impairs endothelial function. This comprises the synthesis of nitric oxide and prostacyclin, resulting in hypertension and loss of vasodilator capacity [30]. Changes in total white blood cell count is known to facilitate diagnosis of fungal, viral or bacterial infections, inflammatory disorders rheumatoids arthritis, leukemia, allergic reaction, inflammatory bowel disease and vasculitis. Increase in total leucocyte count with concomitant decrease in hemoglobin is associated with inflammatory response [31], although increased in total leucocyte count did not reduce hemoglobin concentration in the third week.

The significant reduction in RBC count could be associated with increase *in vivo* hemolysis and increase spleen clearance of red blood cells [32] as evidence by increase in the activity of aspartate aminotransferase and bilirubin level in the treated group respectively. These reasons also explain the significant decrease in hemoglobin concentration of the treated group when compared to the control. Elevated red blood cell distribution width (RDW) has been used to predict mortality in patients with acute decompensated heart failure [33], but there is no significant difference between RDW of test and control. Decrease in RBC count, HCT and HGB are associated with anemia [34] and these predict mild renal failure. Shaheda *et al.* [35] has classified renal failure with these indices; mild renal failure (HGB 9.88-10.85, HCT 29-33 and RBC 3.44-4.30), moderate renal failure (HGB 7.39-7.50, HCT 23-28 and RBC 2.61-3.99) and chronic renal failure (HGB 6.20-7.39, HCT 20-22.85 and RBC 2.23-2.79). The reduction in red blood cell indices could be due to impairment in the synthesis of erythropoietin, a hormone synthesized in the kidney that stimulates synthesis of red blood cell in the marrow. There was no significant ( $p < 0.05$ ) difference between the test and the control in terms of lymphocytes, monocytes and granulocytes throughout the study.

Histopathological analysis of the studied organs revealed vascular congestion in the liver, kidney and heart. Sub-chronic administration of the extract has revealed damage to the liver, kidney, spleen and the heart. Lymphocytes are the first and most commonly observed in leukocytes infiltration, followed by neutrophile, plasmocytes, macrophages and even eosinophil [36]. The vascular congestion in the liver, kidney and heart could have resulted from massive vascular destruction leading to high amount of cellular debris and thus chemotaxis [37]. Sub-chronic administration of *S. longipedunculata* crude alkaloids results in multiple pro-inflammatory insults to the kidney and the liver. These insults are associated with endothelial activation, leukocyte adhesion and subsequent infiltration resulting in hepatic damage (fibrosis) and renal injury.

## 5.0 Conclusion

The crude extract of *S. longipedunculata* has both *in vitro* and *in vivo* antiplasmodial activity, although the toxicity elicited by the extract cannot be neglected. Long term administration of *S. longipedunculata* crude alkaloids may result in multiple pro-inflammatory insults to the kidney and liver, as revealed by the biochemical indices. These insults are associated with endothelial activation, leukocyte adhesion and subsequent infiltration resulting in hepatic damage (fibrosis) and mild renal injury. Thus, alkaloids from *S. longipedunculata* have potential in the management of *P. falciparum* and *P. berghei* infection, and also moderately safe to high LD<sub>50</sub>.

## Acknowledgement

This work was supported by Ibrahim Badamasi Babagida University, Lapai, Nigeria under NEEDS Assessment Grant 2016.

## Conflict of Interest

The authors declare no conflict regarding the publication of this paper.

## References

- [1] Sudaratana, R.K. and Jerapan, K. (2011). Malaria parasite carbonic anhydrase: Inhibition of aromatic heterocyclic sulfonamides and its therapeutic potential. *Asian Pacific Journal of Tropical Biomedicine*, Vol. 1, No.3, pp. 233-242.
- [2] Akkawi, M., Jaber, S., Abu-Lafi, S., Qutab, M., Abu-Rmeleh, Q. and Lutgen, P.L. (2014). HPLC separation and *in vitro* antimalarial studies of *Artemisia annua* plants from two different origins: Cameroon verse Luxembourg. *Malaria World Journal*, Vol. 5, pp. 11.
- [3] Thota, S. and Yerra, R. (2016). Drug discovery and development of antimalarial agents: Recent advances. *Current Protein and Peptides Science*, Vol. 17, pp. 1-7.
- [4] WHO (2017). World Malaria Report 2, 2017.
- [5] WHO (2015). Global Technical Strategy for Malaria 2016-2030.
- [6] Naghibi, F., Esmaeili, S., Abdullah, N., Nateghpour, M., Taghvai, M., Kamkar, S. *et al.* (2013). *In vitro* and *in vivo* malarial evaluation of Myrtle extract, a plant traditionally used for treatment of parasitic disorders. *Techniques in Plants Metabolomics*, pp.25-26.
- [7] Vangapandu, S., Meenakshi, J., Kaur, K., Patil, P., Sanjay, R.P. and Rahul, J. (2007). Recent advances in antimalarial drug development. *Medicinal Research Reviews*, Vol. 27, No.1, pp. 65-107.
- [8] Kaur, K. Jain, M., Kaur, T. and Jain, R. (2009). Antimalarial from nature. *Bioorganic and Medicinal Chemistry*, Vol.17, No. 9, pp. 3322-3356.
- [9] Onguine-Amoe, P., Ntiekong, F., Lifongo, L., Ndon, J., Sippl, W. and Mbaze, L. (2013). The potential of antimalarial compounds derived from Africa medicinal plants: A Pharmacological evaluation of alkaloids and terpenoids. *Malaria Journal*, Vol. 12, No. 1, pp. 449-470.
- [10] Sanusi, J., Jibia, A.B., Runka, J.Y., Ladi, S., Abubukar, A.A. and Rabiu S.Z. (2015). Antimicrobial activity of aqueous and ethanol extract of violet plant (*Securidaca longipedunculata* Fres) on tested pathogenic bacteria. *International Journal of Pharmaceutical Sciences and Research*, Vol. 6, No. 8, pp. 3276-3284.
- [11] Abonyi, O., Uzoegwu, P.N., Ezugwu, A.I., Uroko, R.I., Ani, O.O., Onyemuche, T.N. *et al.* (2014). *In vitro* antioxidant profile of methanolic leaf extract of *Securidaca longipedunculata*. *Journal of Dental and Medical Sciences*, Vol. 13, No. 11, pp. 75- 81.
- [12] Okoli, C., Akah, P. and Ezugworie, U. (2005). Anti-inflammatory activity of extracts root bark of *Securidaca longipedunculata* Fre (Polygalaceae). *African Journal of Traditional Complementary and Alternative Medicine*, Vol. 2, No. 3, pp. 54-63.
- [13] Karou, S.D., Tchacondo, T., Tchiboza, M.A.D, Anani, K., Ouattara, L.,Simpore, J. *et al.* (2012). Screening of Togolese medicinal plants for new pharmacological properties. *Pharmacognosy Research*, Vol. 4, pp. 116-122.
- [14] Adiele, R.C., Faka, B.B. and Isuzu, I.U. (2013). Antihelminthic activity of *Securidaca longipedunculata* (Family polygalaceae) root extract in mice *in vitro* and *in vivo*. *Asian Pacific Journal of Tropical Medicine*, Vol. 6, No. 11, pp. 841-846.
- [15] Ernest, D., Olfert, D.V., Brenda, M., Cross, V.M. and McWilliam, A. A. (1993). *Guide to Care and Use of Experimental Animals*. 2<sup>nd</sup> edition, Canadian Council on Animal Care.



- [16] Yubin, J.I., Miao, Y., Bing, W. and Yao, Z. (2014). The extraction, separation and purification of alkaloids in natural medicine. *Journal of Chemical and Pharmaceutical Research*, Vol.6, No.1, pp. 338-345.
- [17] Chinedu, E. Arome, D. and Ameh, F.S. (2013). A new method for determining acute toxicity in animal models. *Toxicology International*, Vol. 20, No. 3, pp. 224-226.
- [18] Singh, A. and Rosenthal, P.J. (2001). Comparison of efficacies of cysteine protease inhibitors against five strains of *Plasmodium falciparum*. *Antimicrobial Agents and Chemotherapy*, Vol. 45, pp. 949–951.
- [19] Fidock, D.A., Rosenthal, P.J., Croff, S.L., Brun, R. and Nwaka, S. (2004). Antimalarial drug discovery: Efficacy models for compound screening. *Nature Review*, Vol. 3, pp. 509-520.
- [20] Young, B., Lowe, J.S., Stevens, A. and Heath, J.W. (2006). *Wheater’s Functional Histology*, 5th ed, Elsevier, pp. 152-310.
- [21] Bah, S., Jäger, A.K., Adersen, A., Diallo, D. and Paulsen, B.S. (2007). Antiplasmodial and GABA A-benzodiazepine receptor binding activities of five plants used in traditional medicine in Mali, West Africa. *Journal of Ethnopharmacology*, Vol. 110, pp. 451-457.
- [22] Ancolio, C., Azas, N., Mahiou, V., Ollivier, V., Di Giorgio, C., Keita, A. et al. (2002). Antimalarial activity of extracts and alkaloids isolated from six plants used in traditional medicine in Mali and Sao Tome. *Phytotherapy Research*, Vol. 16, pp. 646-649.
- [23] Zemicheal, G. and Mekonnen, Y. (2018). Antiplasmodial activity of *Vernonia adoensis* aqueous, methanol and chloroform leaf extract against Chloroquine sensitive strain of *Plasmodium berghei* in vivo in mice. *BMC Research Notes*, Vol. 11, pp. 736.
- [24] Olivia, N.U., Chileletogo, N.O.F. and Ikechukwu, U.R. (2017). Effect of alkaloid rich fraction (ARF) of methanol extract of *Ricinus communis* seed on immune responses, inflammatory reaction and liver functions. *Journal of Applied Sciences*, Vol. 17, No. 8, pp. 384-391.
- [25] Zengt, T., Wut, X.Y., Yang, S., Lai, W., Shi, S., Zou, Q. et al. (2017). Monoterpenoidindole alkaloids from *Kopsia officinale* and the immunosuppressive activity of Rhazinilam. *Journal of Natural Products*, Vol. 80, No. 4, pp. 864-871.
- [26] Kumar, V.J. and Padmini, M.P. (2012). A histopathological study on Gentamycin induced nephrotoxicity in experimental albino rats. *Journal of Dental and Medical Sciences*, Vol. 1, No. 1, pp. 14-17.
- [27] Greaves, P. (2012). *Histopathology of preclinical toxicity studies*, 4<sup>th</sup> ed, Amsterdam, Elsevier, pp. 5670.
- [28] McGill, M. R. (2016). The past and present of serum aminotransferase and the future of liver injury biomarkers, *EXCLI Journal*, Vol. 15, pp. 817-828.
- [29] Beydoun, M.A., Beydoun, H.A., Dore, G.A., Canas, J.A., Fanelli-Kuczmariski, M.T., Evans, M.K. et al. (2016). White blood cell inflammatory markers associated with depressive symptom in a longitudinal study of urban adults. *Translational Psychiatry*, Vol. 6, pp. 1-11.
- [30] Shankar, A., Klein, B.E. and Klein, R. (2004). Relationship between white blood cell count and hypertension. *American Journal of Hypertension*, Vol. 17, pp. 233-239.
- [31] Sahin, F., Yazar, E. and Yildiz, P. (2012). Prominent features of platelet count, plateletcrit, mean platelet volume and platelet distribution width in pulmonary tuberculosis. *Multidisciplinary Respiratory Medicine*, Vol. 7, pp. 38.
- [32] Srikumar, K., Athithan, V., Premalatha, R., Victor, M. (2015). Homocastasterone: A novel plant ketosteroid inducing haematological changes in normal and diabetic male rats. *International Journal of Pharmacy and Pharmaceutical Sciences*, Vol. 7, No. 7, pp. 1-5.
- [33] Uremura, Y., Shibata, R., Takomoto, K., Uchikwa, T., Koyasu, M., Watanabe, H. et al. (2016). *Journal of Cardiology*, Vol. 67, pp. 268-273.
- [34] Matos, J.F., Dusse, L.M.S., Borges, K.B.G., de Castro, R.L.V., Coura-Vital, W. and Carvalho, M.G. (2016). A new index to discriminate between iron deficiency anemia and thalassemia trait. *Brazilian Journal of Hematology and Hemotherapy*, Vol. 38, No. 3, pp. 214-219.
- [35] Shaheda, K., Begum, N. and Amm, E.H. (2016). Relationship of hemoglobin, packed cell volume and total count of RBC with severity of chronic renal failure. *Chattagram Ma’a-o-Shishu Hospital Medical College Journal*, Vol. 12, No. 2, pp. 31-34.
- [36] Liu, A. and Wei, L. (2010). Leukocyte infiltration as a surrogate marker for diagnosis of invasion. *International Journal of Biological Sciences*, Vol.6, No.3, pp. 225-227.
- [37] Gronberg, N.V., Johansen, F.F., Kristiansen, U. and Hasseldam, H. (2013). Leukocytes infiltration in experimental stroke. *Journal of Neuroinflammation*, Vol. 10, No. 1, pp. 115.