

Review

Human Microsporidial Infections

Authors

Omalu ICJ,

Unit of Entomology and Parasitology, University of Jos, Nigeria

Duhlinska DD,

Unit of Entomology and Parasitology, University of Jos, Nigeria

Anyanwu GI,

Unit of Entomology and Parasitology, University of Jos, Nigeria

Pam VA,

Veterinary Research Institute, Vom – Plateau State, Nigeria

Inyama PU,

Unit of Entomology and Parasitology, University of Jos, Nigeria

Address For Correspondence

Omalu ICJ

Unit of Entomology and Parasitology,

University of Jos, Nigeria

E-mail: omalu_icj@hotmail.com

Citation

Omalu ICJ, Duhlinska DD, Anyanwu GI, Pam VA, Inyama PU. Human Microsporidial Infections. *Online J Health Allied Scs.* 2006;3:2

URL

<http://www.ojhas.org/issue19/2006-3-2.htm>

Open Access Archives

<http://cogprints.ecs.soton.ac.uk/view/subjects/OJHAS.html>

<http://openmed.nic.in>

Submitted: Nov 09, 2005; Revised: Jan 19, 2006; Accepted: Jan 22, 2006; Published: Mar 31, 2006

Abstract:

Microsporidia are eukaryotic, spore forming obligate intracellular parasites, first recognised over 100 years ago. Microsporidia are becoming increasingly recognised as infectious pathogens causing intestinal and extra-intestinal diseases in both immuno-competent and immuno-suppressed patients. They are characterised by the production of resistant spores that vary in size depending on the species; and poses a unique organelle, the polar tubule (polar filament), which is coiled inside the spore as demonstrated by its ultra structure. Other unusual characteristics are the lack of mitochondria and the prokaryotic-like ribosomes, which indicate the primitive nature of the group. Presently there are seven genera, *Enterocytozoon*, *Encephalitozoon*, *Nosema*, *Pleistophora*, *Trachi pleistophora*, *Brachiola*, *vittaforma* species which have been reported from human hosts as agents of systemic, ocular, intestinal and muscular infections are described and the diagnosis, treatment, and source of infections discussed.

Key Words: Microsporidia, *Enterocytozoon*, *Encephalitozoon*, *Nosema*, *Pleistophora*, Diagnosis

Introduction:

Microsporidia are intracellular spore-forming protozoa that are increasingly being recognized as pathogens in humans. They are ubiquitous in the environment and can infect a wide range of vertebrate and invertebrate hosts, including insects, birds, fish and mammals. The spores vary in size, but those that infect humans are typically oval and one to two μm in diameter. They are highly resistant to degradation, and can survive in the environment for up to four months. Their structure is distinguished by the presence of a polar filament within the spore which is involved in injecting spore contents into the host cell.

Although microsporidia were discovered more than 100 years ago, the first well documented case of human microsporidiosis was reported in 1959.¹ It could not have been anticipated when these organisms were first described that they would be recognized as the agents of distressing and life-threatening human

diseases. The AIDS epidemic has revealed their propensity for infecting man, although it is still not known whether microsporidia cause strictly opportunistic zoonosis or exist in healthy people as latent infections, which becomes exacerbated when the patients becomes immuno-compromised. The ability of these parasites to cause disease in immuno-competent persons is still being elucidated. Microsporidia can cause a variety of human diseases, involving multiple organ systems, which include intestinal, ocular, sinus, pulmonary, muscular and renal diseases in both immuno-competent and immuno-compromised patients.² The first case of intestinal microsporidiosis in Nigeria was reported in 2002.³

This review aimed to summarise the unusual features of the biology of microsporidia, update ourselves with the new clinical manifestation, latest techniques of identification and the new treatment modalities to overcome these infections.

Classification and Taxonomy:

The viability of the silk industry was threatened in the 19th century, because of a mysterious disease of silk worms, *Bombyx mori*. The causative agent was first named microsporidian *Nosema bombycis*, which was classified as Schizomycetes which, at the time include yeasts and bacteria.⁴ The order Microsporidia was defined and separated into the Phylum Microspora within the zoological kingdom, protozoa.^{5,6} Landmarks in the recording of microsporidian species since these early beginnings are the monograph of Kudo⁷ in which 14 genera and about 170 species were listed, Sprague, in which 44 genera and over 700 species were listed⁶, Canning and Hollister, in which 96 genera and almost 1000 species were listed⁸ and to date 143 genera and more than 1200 species have been described as parasites infecting a wide range of vertebrate and invertebrate hosts.⁹ Microsporidia were classified and grouped taxonomically on the basis of their natural host and ultra structural features such as size of the developing and mature organisms, nucleus arrangement

(monokaryon or diplokaryon), number of polar filament coils, interface with the host cell during development (direct contact with host cell cytoplasm, replication within a host cell derived parasitophorous vacuole, replication of organisms surrounded by endoplasmic reticulum, sporogony within a parasite generated sporophorous vesicle and mode of cell and nuclear division (binary division, karyokinesis with delayed cytokinesis).¹⁰ Molecular biology methods have subsequently been used to further classify the microsporidia. The eukaryotic microsporidia that possessed prokaryotic-like ribosomes because the ribosomal genes encoded 16S and 23S subunits without an independent 5.3S subunit that is typically observed in eukaryotes has been reported.^{11,12} These results suggested that the microsporidia were early branching protozoa.

Morphology of Genera and Species Infecting Man:

Encephalitozoon Species

Encephalitozoon is parasitic in vertebrates. Development occurs in parasitophorous vacuoles in host cells. Meronts lie close to the vacuolar membrane, which is of host origin, and divide mainly by binary fission. Sporonts become free in the centre of the vacuole, divide into two sporoblasts (disporoblastic), which mature into spores. Mature parasitophorous vacuoles are packed with spores. Nuclei of all stages are unpaired.

Examples are *Encephalitozoon cuniculi* which measure approximately 2.5–3.2 x 1.2–1.6µm with 4.5–5 coils of the polar tube, although 5–7 coils have been recorded in isolates from dogs and *Encephalitozoon hellem* which are more rounded, measuring 2.0 – 2.5 x 1.0 – 1.5µm.⁸

Enterocytozoon Species

Enterocytozoon is a parasite of vertebrates. Development takes place in direct contact with host cell cytoplasm. Meronts and sporonts are multinucleate, traversed by

electron-lucent slits, which are probably expanded and irregularly elongate. There is markedly precocious development of spore organelles in sporonts, including morphogenesis of polar-tube from electron-dense discs. The endospore layer of the spore wall is poorly developed. Example is *Enterocytozoon bieneusi* known only from small intestinal enterocytes of AIDS patients. Spores measure approximately 1.1 - 1.6 x 0.7 - 1.0µm, are ellipsoidal with 5 – 7.5 coils of the polar tube.⁸

Nosema Species

Numerous species have been described chiefly in invertebrates. Development occurs in direct contact with host-cell cytoplasm, i.e., there are no parasitophorous vacuoles or sporophorous vesicles. Nuclei are paired (diplokaryotic). Sporonts are disporoblastic. Examples are *Nosema connori* spores are oval with 11 coils of the polar tube and *Nosema corneum* with about 6 coils of the polar tube they measure 4.0 - 4.5 x 2.0 - 2.5µm.⁸

Pleistophora Species

Pleistophora is a parasite of vertebrates, chiefly fish. A thick amorphous surface coat surrounds Meronts, which are multi-sporous culminating in a large and variable number of spores within the persisting vesicle. Nuclei are unpaired. *Pleistophora* species has been found, parasitic in the muscles of an immuno-compromised, but HIV – negative man. The oval spores appear less rounded with 11 coils of the polar tube and measure approximately 3.2 – 3.4 x 2.8µm.⁸

Microsporidium Species

Microsporidium is a collective generic name given to species for which the genus cannot be determined on available information. Examples are *Microsporidium ceylonensis* and *Microsporidium africanus*. Spores have 11–13 coils of the polar tube and measure about 3.5 x 1.5µm.⁸ Table 1 shows the pathologic spectrum of microsporidia infecting man.

Table 1: Pathologic Spectrum of Microsporidia Infecting Man¹³

Species	Size of Spore(µm)	Habitat	References
<i>Enterocytozoon bieneusi</i>	1.1-1.6x0.7-1.0	Small intestinal epithelial epithelium	Orenstein <i>et al.</i> , 1990
		Small intestinal sub epithelial infection	Schwartz <i>et al.</i> 1994 b
		Biliary tract epithelium	Pol <i>et al.</i> 1993; Bryan <i>et al.</i> , 1993 and Mcwhinney <i>et al.</i> , 1991
		Gall bladder epithelium	Pol <i>et al.</i> 1993 and Bryan <i>et al.</i> , 1993
		Pancreatic duct epithelium	Bryan <i>et.</i> a1993
		Bronchial epithelium	Weber <i>et al.</i> , 1993
<i>Encephalitozoon hellem</i>	2.0-2.5x1.0-1.5	Corneal and conjunctival epithelium	Schwartz <i>et al.</i> , 1993b and Cali <i>et al.</i> , 1993b.c
		Sino-Nasal epithelium	Canning <i>et al.</i> , 1992 and Schwartz <i>et al.</i> , 1993a
		Tracheo-bronchial mucosa	Schwartz <i>e. al.</i> , 1992 and 1993c.d
		Renal tube infection	Schwartz <i>et al.</i> , 1992
		Urethral and urinary bladder mucosa	Schwartz <i>e. al.</i> , 1992
		Protastic abscess	Schwartz <i>et al.</i> , 1994 a
<i>E. cuniculi</i>	2.5-3.2x1.2-1.6	Bronchial and Bronchiolar epithelium	DeGroot <i>et. al.</i> , 1995
		Tongue	DeGroot <i>et al.</i> , 1995
		Peritonitis	Zender <i>et al.</i> , 1989
<i>E. intestinalis</i>	1.2 x 2.2	Hepatitis	Terada <i>et al.</i> , 1987
		Small intestine	Accoceberry <i>et al.</i> , 1999
<i>Nosema conori</i>	4.0-4.5x2.0-2.5	All organs	Canning and Hollister, 1992
<i>N. corneum</i>	3.7 x 1.0	Corneal Stroma	Canning and Hollister ,1992
<i>Pleistophora Sp.</i>	3.2 – 3.4 x 2.8	Skeletal Muscles	Chupp <i>et al.</i> , 1993
<i>Microsporidium ceylonensis</i>	3.5 x 1.5	Corneal Stroma	Canning and Hollister, 1992
<i>M. africanum</i>	4.5 x 2.5	Corneal Stroma	Canning and Hollister, 1992.

Biology of Microsporidia:

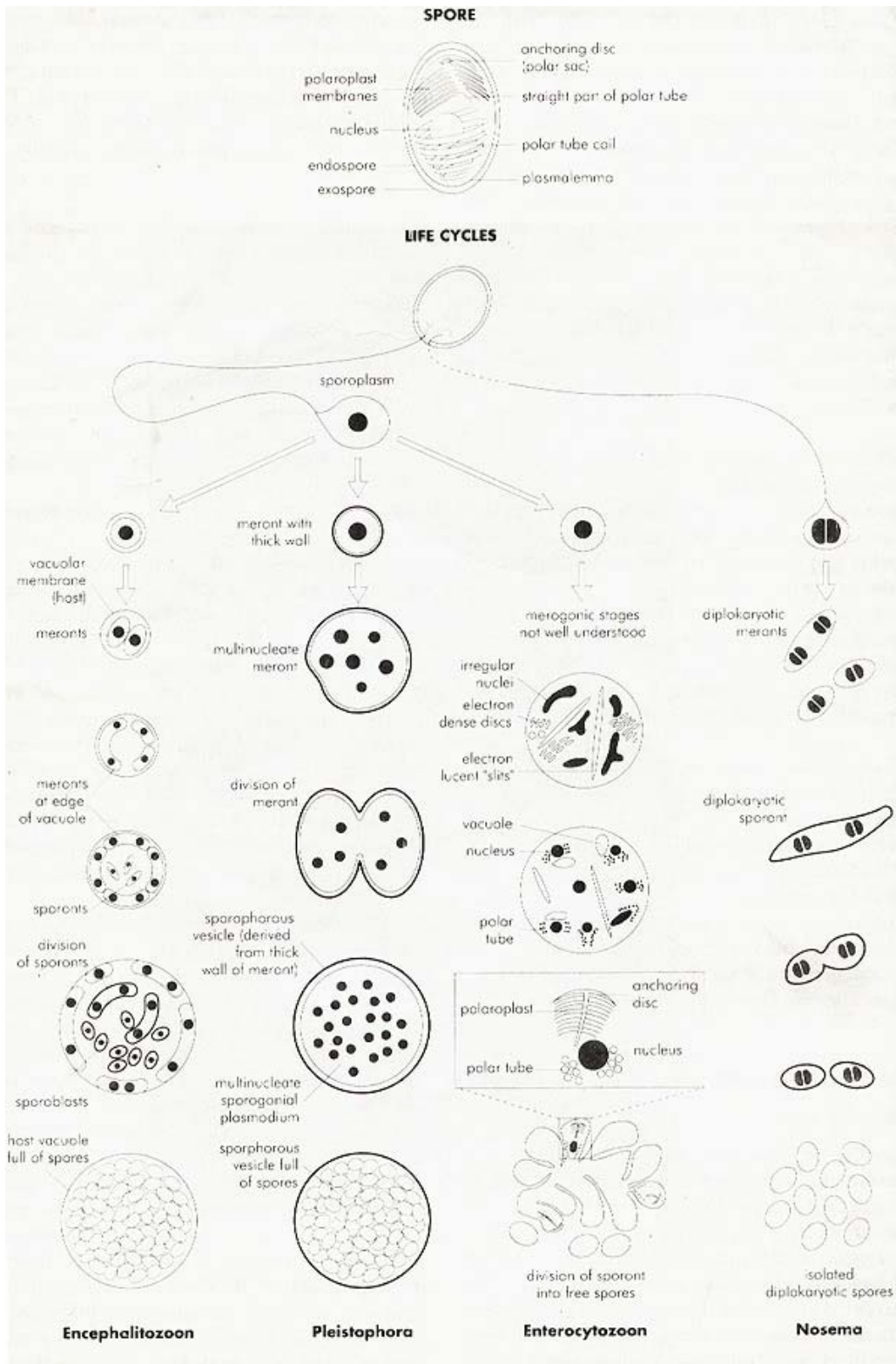
Spores have a resistant wall composed of an outer proteinaceous exospore and a thicker electro-lucent endospore, which contains chitin. The wall surrounds the infective sporoplasm, which may be uninucleate or binucleate, and an extrusion apparatus, which controls infection of new cells. The extrusion apparatus consists of a polar tube, coiled in the posterior half of the spores and connecting via a straight section with an anterior anchoring disc, the polar sac. The straight section of the polar tube is surrounded by an array of membranes being continuous with the outer membrane of the polar tube. When stimulated by the cells, usually in the gut of a new host, the polar tube is everted and the sporoplasm passes through it and, if the tip of the tube chances to penetrate a host-cell membrane, the sporoplasm is inoculated into the cell. This infection mechanism is unique in the animal kingdom.

The spore is the only stage surviving in the open air and serving to aid transmission to the new host in contaminated water and food. In water, spores usually live more than one year at 4°C; in infected tissues, they survive even longer. Spores also pass across the placenta in animals to infect the foetus and infection acquired transplacentally is severe. Spores are refringent, oval, usually all of the same

size and shape. Sporoblasts are usually larger and the measurements together with mature spores bring disputed variability in descriptions of spore size. In ultra-thin sections, mature spores are usually dark and not differentiated in their interior, and only young spores are differentiated in the cross sections of the polar filaments. The number of coils in cross-section and the location (parallel coils, tilt) is characteristic for the species.^{8,14}

In development, they have a proliferative phase of binary or multiple fission, termed merogony; the stages have simple unit membranes at the surface and little differentiation of the cytoplasm. This is followed by a sporulation phase, initiated when a dense surface coat is secreted on cells called sporonts, which divided into sporoblasts that mature into spores as described above. In some genera, the spores lie free in the host-cell cytoplasm; in others, the spores derived from a single sporont are grouped together within a sporophorous vesicle of parasite origin [Figure 1]. The vesicle arises as an additional envelope on the surface of the sporonts and separates from the surface as development progresses. Microsporidia spread rapidly in most tissues as a result of the extensive proliferation in merogony and sometimes when there is autonomous, hatching of spores.⁸

Fig 1: Spore structures and life cycles of Microsporidia (Source: Canning and Hollister,1992)



Life Cycle of Microsporidia:

1) Spores are ingested by a host (man or animal). 2) The spore extrudes its polar tubule and infects the host cell. 3) The spore injects the infective sporoplasm into the eukaryotic host cell through the polar tubule. 4) Inside the host cell, the sporoplasm undergoes extensive multiplication either by merogony (binary fission) or schizogony (multiple fission). 5) This development can occur either in direct contact with the host cell cytoplasm (e.g. *Ent. bienewsi*) or inside a vacuole termed parasitophorous vacuole (e.g

E. intestinalis). Either free in the cytoplasm or inside a parasitophorous vacuole, microsporidia develop by sporogony to mature spores. 6) During sporogony, a thick wall is formed around the spore, which provides resistance to adverse environmental conditions. When the spores increase in number and completely fill the host cell cytoplasm, the cell membrane is disrupted and releases the spores to the surrounding [Figure 2]. 7) These free mature spores can infect new cells thus continuing the cycle.⁹

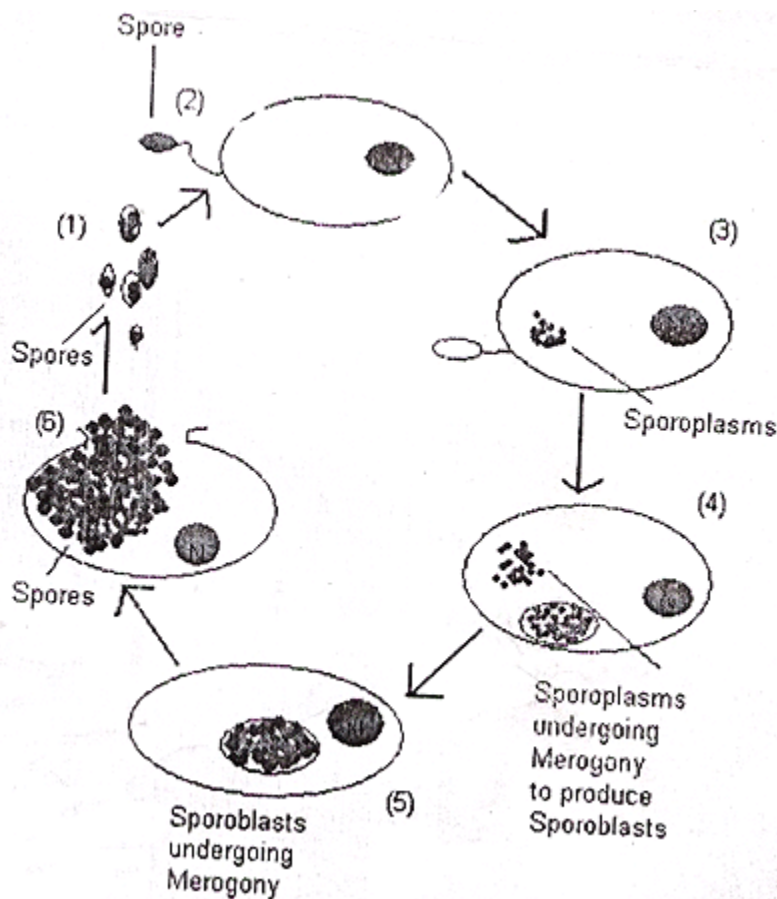


Figure 2: Generalized life cycles of microsporidia

Geographic Distribution:

Microsporidia are being increasingly recognized as opportunistic infectious agents worldwide. Cases of microsporidiosis have been reported in developed as well as in developing countries, including: Argentina, Australia, Botswana, Brazil, Canada, Czech Republic, France, Germany, India, Italy, Japan, The Netherlands, New Zealand, Spain, Sri Lanka, Sweden, Switzerland, Thailand, Uganda, United Kingdom, United States of America, and Zambia.⁹ Lately cases of microsporidia have been reported in Nigeria.^{3,15}

Origin/ Sources of Acquisition of Microsporidia:

Faecal oral transmission is the likely route of infections in humans with intestinal microsporidiosis when spores contaminate the environment. Infection can occur by both inhalation and ingestion. *Encephalitozoon cuniculi* is known to pass across the placenta in animals to infect the foetus. *E. cuniculi* infects a wide range of mammals, including carnivores, and dogs are likely source of infection to man.

The microsporidium *Enterocytozoon bieneusi* is known from AIDS patients only. It is thought that it might have a worldwide distribution. This and its high prevalence suggest that it may be a natural parasite of man, perhaps causing transient diarrhoea, but normally remaining below the detection level, only becoming a problem in severely immuno-compromised people. It is not known whether there is an animal reservoir. The only other known species infects salmonid fish but as well as being an unlikely source of human infection, it has different morphological characteristics. The sources of the eye infections are just as mysterious. A Tamil boy had been gored in the eye by a goat 6 years before onset of his infection and it suggested that the

microsporidia might have been acquired from the goat, because tapeworms infesting goats are frequently hyper-parasitised with *Nosema helminthorum*.¹⁶ However, the spore sizes are widely different. In a later study of *Encephalitozoon cuniculi* in the lenses of a rabbit, the absence of infection in the ocular envelope and not in the lenses indicated that the infection had entered the eye from a systemic source before the lens capsule had matured and thus that the infection had been acquired transplacentally.¹⁷ *Nosema corneum* was isolated from a woman in Botswana who had no previous history of trauma in the eye.¹⁸ A man from whom *Nosema corneum* was isolated also had no history of trauma; and the probable source of infection could be from his travel to the Caribbean and Central America, where infections in invertebrates were likely to be more common, and also the fact that he lived near (and perhaps swam in) a large recreational lake, in which spores of invertebrate origin could have been abundant.¹⁹ The restriction of *Nosema corneum* to the epithelium of the cornea and conjunctiva suggests that infections are acquired topically. Of other cases observed, one person had owned a parrot; another had looked after a cat for several days but only after his infection had developed. There did not appear to be a common animal source for the infections.

Pleistophora species are common parasites of fish, in which the myofibrils are infected in a similar manner to the deltoid and quadriceps muscles of a man.²⁰ As the man was immuno-compromised, it is possible that infection was acquired by eating fish but the fish would have had to be uncooked.

Clinical Aspects of Human Microsporidiosis:

The well documented case of microsporidian infections in humans was reported in 1959, in a Japanese boy exposed to farm animals who presented with headache, convulsion and recurrent fever. Examination of the cerebrospinal fluid revealed organisms identified as microsporidia, genus *Encephalitozoon*.¹ The next two reports were in 1973: An immuno-compromised infant with athymic aplasia died of severe diarrhoea and malabsorption.²¹ The microsporidium *Nosema connori* were identified in most organs. The other report was of corneal involvement in a 11-year old boy of Sri-Lanka.¹⁶ Human microsporidiosis can be classified as below:

Systemic Infection

A single case was described of a newborn infant with thymic deficiency and presented with acute respiratory distress, diarrhoea and malabsorption. The respiratory problem was linked with *Pneumocystis carinii* infection. The patient died at 4 months of age and a post-mortem examination revealed an overwhelming disseminated infection with microsporidia, *Nosema connori* in almost every organ. There was a predilection for muscular tissue but the kidney, adrenal cortex, lungs and liver were also infected. The spleen was not infected and the central nervous system was not examined. Although, pneumocystis pneumonia may have been the primary cause of death, there is little doubt that the microsporidiosis was the contributory cause.²¹ The combined immunodeficiency, with marked leucopenia and hypogammaglobulinaemia, due to the defective lymphoid system, clearly enabled the microsporidia to take hold and multiply, but the mystery lies in the source of the infection. The child fell ill shortly after birth, so that it is not clear whether the infection was

acquired transplacentally or perinatally. Four cases, identified as *E. cuniculi* have been reported in man. The identifications were based on morphological data before evidence was presented of the existence of a second species, *E. hellem*, in man.^{1, 22, 23}

Ocular Infections

Several different types of microsporidia have been found in the human eye. Interestingly, the infections in immuno-competent people have extended deeply into the corneal stroma, whereas those in AIDS patients have been restricted to the superficial epithelium. The cornea of the right eye of an 11-year-old Tamil boy in Sri-Lanka was scarred and vascularised, and granulomatous tissue was present over the conjunctival surface of the upper lid.¹⁶ The spores lay free and in macrophages deep in the cornea but not below Descemet's membrane. The genus of the organism could not be identified and was later placed in the collective *Microsporidium* and named *M. ceylonensis*.²⁴

The left eye of a 26-year-old woman in Botswana was removed because of a painfully inflamed conjunctiva and no light perception.¹⁸ A perforated corneal ulcer was found, adjacent to which the corneal stroma was necrotic and infiltrated with inflammatory cells. Again, the stroma was packed with microsporidial spores both free and phagocytosed. The genus was not established, although *Nosema* was suggested, and the isolate was later named *Microsporidium africanum*.²⁴

Bilateral infections in the superficial epithelium of the cornea and conjunctiva of AIDS patients have been reported several times in patients in the United States.^{25, 26} The clinical manifestations in five of these patients have been summarized.²⁷ All had conjunctival inflammation and decreased visual acuity and diffuse

punctate keratopathy. One patient had corneal inflammation and another had corneal ulceration. These microsporidial infections are visible as fine or coarse epithelial opacities causing redness and irritation of the eye and most patients also suffered photophobia. Corneal or conjunctival scrapings appeared identical to *E. cuniculi* when examined by electron microscopy, but the new isolates were differentiated from *E. cuniculi* on their protein profiles separated by SDS – PAGE and by immunoblotting. The new species was named *E. hellem*.²⁸ An infection, probably due to the same species has also been identified in Britain.²⁹ In this case, the infection also spread to the basal mucosa, which became inflamed and hypertrophic. Examination showed multiple nasal polyps and a CT- Scan showed opacities in the nasal sinuses. The chronic nasal obstruction did not respond to antimicrobial therapy.³⁰

Intestinal Infections

Intestinal infections have been found only in AIDS patients and the commonest of these is due to *Enterocytozoon bieneusi*. This species was described and named by Desportes *et al.*, and further studies at the ultra structural level by Curry *et al.*^{31,32} First diagnosed in a Haitian man in France, the species has, to date, been found in about 150 patients. It causes severe watery, non-bloody diarrhoea, which is exacerbated by food intake. There is slow weight loss of about 1kg per week. In groups of patients with persistent diarrhoea, who were negative for other specific enteric pathogens by normal microbial examinations, prevalence of *Ent. bieneusi* ranged between 27% - 30%.^{27,33}

Parasites are restricted to the small intestinal enterocytes and were rather more common in the jejunum than in the duodenum. They lie between unaltered brush-border and the cell nucleus, which is often indented by the

parasites. Several parasites can be found in one cell. There is no bulbous appearing as ridges or long tongues of tissue.²⁷ Infected cells are sloughed into the lumen of the intestine. The diarrhoea caused by this species is debilitating and life threatening, with as many as ten episodes each day, and does not respond satisfactorily to therapy. It must be considered as a significant cause of deaths in these patients. Two additional infections by unidentified microsporidia have been reported in the intestine of AIDS patients. The species involved in the first case was reported to exceed the level of infection normally achieved by *Ent. bieneusi* in the jejunum and duodenum and invades the histiocytes as well as the enterocytes.²⁷ Identification in the second case was not possible on available evidence and, as it occurred as a double infection with *Ent. bieneusi*, its pathogenicity could not be assessed.³⁴

Muscle Infections

A 20-year-old man with a low T-helper/suppressor cell ratio presented with an illness of 7 months duration characterised by generalized muscle weakness and contractures, generalized non-tender lymphadenopathy, fever and an 18kg loss of weight.²⁰ Muscle biopsy from the arm, taken on admission and 5 months later showed masses of spores amid trophic and degenerating muscle fibres with an intense inflammatory reaction. The spores were identified as *Pleistophora* species, as they were grouped in large numbers within sporophorous vesicles. Ten months after diagnosis, and after some antibiotic therapy, he was afebrile and the myopathy had improved slightly.

Laboratory Diagnoses of Microsporidiosis:

Diagnosis of microsporidia in general is based on the microscopic identification of the organism, the electronic microscopic findings, nucleic acid methods and serological assays. Several groups of workers have therefore developed microsporidial spore staining methods for examination of faecal samples. Spores has also been detected in sputum, nasal washings, conjunctival scrapings and vaginal swab samples. Microsporidial spores are of the same order of size, as bacteria so that staining has to differentiate between the spores and faecal bacteria. The methods must also allow the microscopist to differentiate between microsporidial spores and those of yeasts and fungi as well as the oocysts of coccidian protozoal parasites.

Spores stain light blue with Giemsa, red with Ziehl Neelsen, magenta with Gram's stains, spore wall stains pink to red and the interior of the spore is unstained with a diagonal line representing the polar tube with Trichrome stain, and spores appear bluish white at a wavelength of 395 to 415 nm with Calcoflor white stain; on their own these stains are not specific but the different colourations collectively build up a reliable diagnostic picture. Any lingering doubts can be removed by revealing spore structure by electron microscopy.

Infections in the eye can be diagnosed by slit-lamp examination and by detection of parasites in corneal or conjunctival scrapings.

A variety of serological tests have been developed to detect residual antibodies to *E. cuniculi*. Of these, the indirect immunofluorescent test (IFAT) and enzyme linked immunosorbent assay (ELISA) are probably the most useful. Both have been used to detect

antibodies in human sera.^{35,36} It has been mentioned that serological testing is most useful. Serological testing is not useful in immunocompromised persons and reagents not available commercially. Immunofluorescence may also be used.

Molecular techniques are beginning to be applied to microsporidial problems, particularly for use in the differentiation of species and their detection in clinical samples. Random amplified polymorphic DNA (RAPD) obtained by means of the polymerase chain reaction (PCR), as well as restriction enzyme digests (RED), have shown clear differences among isolates. Ribosomal DNA gene sequences are available for *Enterocytozoon* and *Encephalitozoon* species. PCR analyses are performed using specific primers. To raise the sensitivity of PCR, powerful and fast DNA extraction method including stool sedimentation, glass bead disruption, and proteinase K and chitinase digestion. Primer pairs V1-PMP2, V1-EB450, and V1-SI500, are used for this analysis, and the nature of the PCR products are confirmed by southern blot hybridization.³⁷

Treatment of Microsporidiosis:

Microsporidial infections are difficult to treat because of their intracellular habit and the resistant nature of the spores. Enteric microsporidial infections have been treated with varying degree of success with several drugs. The most promising antimicrosporidial drug to date is albendazole.³⁴ It does not eliminate infection with *E. bienersi* but in many cases alleviates the diarrhoea. The species, which develop in parasitophorous vacuoles, appear to be more susceptible to albendazole, as indicated by the disappearance of *E. intestinalis* from the intestine³⁸ and regression of hypertrophic nasal epithelium in a patient with sinusitis due to *Encephalitozoon* species.³⁰ Several drugs are reported to reduce

levels of microsporidial infections in invertebrates, notably; Fumagillin which includes topical fumagillin for treatment of keratoconjunctivitis³⁹, Benomyl⁴⁰, Buquinolate⁴¹, Toltrazuril⁴² and Itraconazole.⁴³

No sustained improvement has been reported for the diarrhoea due to *Ent. bieneusi*. Chemotherapy for microsporidial disease is clearly a priority area of research.

Disinfection of Microsporidia:

Disinfection of surfaces contaminated with microsporidia has received little attention. A rabbit isolate of *E. cuniculi* cultured in a rabbit choroid plexus (RCP) cell line has been used for *in vitro* experiments in testing the factors influencing the infectivity and replication of this organism in RCP cells³². Aliquots of cells used for testing contained variable proportions of spores, sporoblasts, sporonts and schizonts, although a typical pool contained about 80% spores, are made visible by electron microscopy. Penicillin, Streptomycin or Gentamicin did not affect *E. cuniculi*, nor was it affected by sonication, freezing and thawing or distilled water. Organisms survive for 60 minutes but not up to 120 minutes at 56 °C. They were killed after 10 minutes of autoclaving at 12 °C or exposure to 2% (v/v) lysol, 10% (v/v) formalin and 70% (v/v) ethyl alcohol for 10 minutes. It is not known whether all microsporidia are affected to the same degrees as *E. cuniculi* by the physical conditions and chemicals used in the study.³²

Animal Model:

Several animal models have been established to study microsporidial infection^{24,44,45} as well as for producing monoclonal antibodies^{13,46,47}. Balb/c and C57B1/6 athymic mice have been used and have been injected intraperitoneally with *Encephalitozoon cuniculi*, *Encephalitozoon hellem* or

Vittaforma cornea. SCID mice were also been infected by oral inoculation of *Encephalitozoon cuniculi* spores.⁴⁸ Successful transmission of *Encephalitozoon cuniculi* to rabbits by administration of spores orally and rectally has been reported.⁴⁴

Conclusions:

Microsporidia are an important cause of disease in AIDS patients and are now increasingly also recognized as pathogens in non-HIV-infected patients with or without immuno-suppression. Therefore, a high index of suspicion is needed for both clinicians, parasitologists, pathologists and microbiologists.

As is true for many other new and emerging pathogens, we have just scratched the surface of a complex and evolving relation between microsporidia and humans. There is need for an in-depth study on application of molecular techniques to diagnosis, species differentiation and phylogenetic analysis of microsporidia which will increase the knowledge of these organisms and help greatly in evaluating its threat to health in Nigeria.

References:

1. Matsubayashi H, Koike T, Mikata I, Takei H, Hagiwara S. A case of *Encephalitozoon* - like body in man. *Archives of Pathology* 1959;67:181-187.
2. Weber R, Bryan RT, Schwatts DA, Owen RL. Human Microsporidial infections. *Clinical Microbiology Reviews* 1994;7:426-461.
3. Omalu ICJ, Duhlińska DD, Anyanwu GI, Yako AB. Prevalence of Microsporidiosis in Immunocounprised patients in Kano State. *Proceedings of the 4th National Conference of the League of Researchers in Nigeria in Law Auditorium of University of Jos.* 28th October, 2002.
4. Nageli KW. Über die neue krankheit der seidenraupe und verwante organismen. *Bot Zeit* 1857;15: 760 – 761.
5. Balbiani M. Sur les microsporidies ou psorospermies des articules. *C R Academy of Science* 1882;95: 1168-1171.

6. Sprague V. Annotated lists of species of microsporidia. In: Bulla LA, Cheng TC, eds. Comparative pathobiology, vol. 2: Systematics of the microsporidia. New York: Plenum press. 1976;331-334
7. Kudo R. A biologic and taxonomic study of the microsporidia. III *Biological Monograph* 1924;9:1-268
8. Canning EU, Hollister WS. Human infections with Microsporidia. *Reviews in Medical Microbiology* 1992;3:35-42,
9. CDC. Microsporidiosis *Parasite and Health*. 2004;1-3pp.
10. Joseph J, Vemuganti GK, Sharma S. Microsporidia: Emerging ocular Pathogens. *Indian Journal of Medical Microbiology* 2005;23:80-91.
11. Vossbrinck CR, Maddox JV, Friedman S, Debrunner-Vossbrinck BA, Woese CR. Ribosomal RNA sequence suggests Microsporidia are extremely ancient eukaryotes. *Nature* 1987;326:411-414.
12. Weiss L, Vossbrinck C. Molecular biology, molecular phylogeny, and molecular diagnostic approaches to the microsporidia. In Wittner M, Weiss L, editors, *The Microsporidia and Microsporidiosis*, Washington DC: *American Society of Microbiology* 1999;pp. 120-271
13. Schwartz DA, Bryan RT, Weber R, Visvesvara GS. Microsporidiosis in HIV positive patients: Current methods for diagnosis using biopsy, Cytologic, techniques. *Folia parasitologica* 1994;41:101-109.
14. Lom J. Introductory remarks on Microsporidia in the AIDS era. *Folia Parasitologica* 1993;40:255-256.
15. Omalu ICJ, Duhlińska DD, Anyanwu GI, Yako AB, Inyama PU. Detection of *Encephalitozoon* species in urine and sputum samples of immunocompromised patients in Kano State. A paper presented at the 2nd Annual Conference of the Zoological Society of Nigeria held at the Institute of Development Research at Ahmadu Bello University Zaria on 8th - 9th of November, 2004.
16. Ashton N, Wirasinha PA. Encephalitozoonosis (nematosis) of the cornea. *British Journal of Ophthalmology* 1973;57:669-674
17. Ashton N, Cook C, Clegg F. Encephalitozoonosis (nematosis) causing bilateral cataract in a rabbit. *British Journal of Ophthalmology* 1976;60:618 - 631.
18. Pinnolis M, Egbert PR, Font RL, Winter FC. Nosematosis of the Cornea. Case report, including electron Microscopic studies. *Archives of Ophthalmology* 1981;99:1044-1047.
19. Shadduck JA, Meccoli RA, Davis R, Font R. Isolation of a Microsporidian from a human patient. *Journal of Infectious Diseases* 1990;162:773-776.
20. Ledford DK, Overman MD, Gonzalvo A, Cali A, Mester SW, Lockey RF. Microsporidiosis myositis in a patient with acquired immunodeficiency syndrome. *Annals of Internal Medicine* 1985;102:628-630.
21. Margileth AM, Strano AJ, Chandra R, Neafie R, Blum M, McCully RM. Disseminated nosematosis in an immunological compromised infant. *Archives of Pathology* 1973;95:145-150.
22. Bergquist NR, Stintzing G, Smedman L, Wallert T. Diagnosis of encephalitozoonosis in Man by Serological tests. *British Medical Journal* 1984;288:902-903
23. Terada S, Reddy KR, Jeffers LJ, Cali A, Schiff ER. Microsporidian hepatitis in the Acquired Immunodeficiency Syndrome. *Annals of Internal Medicine* 1987;107:61-62.
24. Canning EU, Lom J. *The Microsporidia of Vertebrates*. London. Academic Press, 2nd Edition. 1986;289p.
25. Lowder CY, Meisler DM, McMahon JT, Longworth DL, Rutherford I. Microsporidia infection of the cornea in a man seropositive for human immunodeficiency virus. *American Journal of Ophthalmology* 1990;109: 242-244.
26. Friedberg DN, Stenson SM, Orenstein JM, Tierno PM, Charles NC. Microsporidial keratoconjunctivitis in acquired immunodeficiency syndrome. *Ophthalmology* 1990;108:504-508.
27. Orenstein JM, Chiang J, Steinberg W, Smith PD, Rotterdam H, Kotler DP. Intestinal Microsporidiosis as a cause of diarrhoea in human immunodeficiency virus infected patients: a report of 20 cases. *Human Pathology* 1990;21(5):475-481.
28. Didier ES, Didier PJ, Friedberg DN et al. Isolation and characterization of new human microsporidian, *Encephalitozoon hellem* (n.sp) from three AIDS patients with keratoconjunctivitis. *Journal of Infectious Diseases* 1991;163:617-621.
29. Metcalfe, T, Doran R, Rowland P, Curry A, Lacey CJN. (). Microsporidial Keratoconjunctivitis in a British patient with AIDS. *British Journal of Ophthalmology* 1992;76:177-178.
30. Lacey CJ, Clark A, Frazer P, Metcalfe T, Bonsor G, Curry A. Chronic Microsporidian infection in the Nasal Mucosae, Sinuses, and conjunctivae in HIV disease. *Genitourinary Medicine* 1992;68:179-181.

31. Desportes L, LeCharpentier Y, Galian A, Bernard F, Cochand-Priollet B, Larvergae A, Ravisse P, Modigliani R. Occurrence of a new Microsporidian, *Enterocytozoon bieneusi* n.g., n.sp., in the enterocytes of a human patient with AIDS. *Journal of Protozoology* 1985;32:250-254.
32. Curry A, Canning EU. Human Microsporidiosis. *Journal of Infection* 1993;27:229-236.
33. Van-Gool T, Hollister WS, Eeftinck-Schattenkerk J et al. Diagnosis of *Enterocytozoon bieneusi* Microsporidiosis in AIDS patients by recovery of spores from faces. *The Lancet* 1990;336:697-698.
34. Blanshard C, Ellis DS, Tovey DG, Dowell S, Gazzard BG. Treatment of intestinal Microsporidiosis with albendazole in patients with AIDS. *AIDS* 1992;6:311-313.
35. Hollister WS, Canning EU. An Enzyme Linked Immunosorbent Assay (ELISA) for detection of antibodies to *Encephalitozoon cuniculi* and its use in determination of infections in man. *Parasitology* 1987;94:209-219.
36. Hollister WS, Canning EU, Wilcox A. Evidence for Widespread Occurrence of antibodies to *Encephalitozoon cuniculi* (Microspora) in man provided by ELISA and other serological tests. *Parasitology* 1991;102:33-43.
37. Muller A, Stellermann K, Hartmann P et al. A Powerful DNA extraction method and PCR for detection of Microsporidia in clinical stool specimens. *Journal of Infectious Diseases* 1999;44:22-25.
38. Orenstein JM, Dieterich DT, Kotler DP. Albendazole as a treatment for disseminated microsporidiosis due to *Encephalitozoon intestinalis* in AIDS patients. *AIDS* 1993;6:311-313.
39. Katznelson H, Jamieson CA. Control of *nosema* disease of honeybees with fumagilin. *Sciences* 1952;115 70-71.
40. Hsiao TH, Hsiao C. Benomyl: a novel drug for controlling a microsporidian disease of alfafa weevil. *Journal of Invertebrate pathology* 1973;22:303-304.
41. Overstreet RM. Buquinolate as a preventive drug to control microsporidiosis in the blue crab. *Journal of Invertebrate Pathology* 1975;25:213-216.
42. Mehlhorn H, Schmahl G, Haberkorn A. Toltrazuril effective against a broad spectrum of Protozoan parasites. *Parasitological Research* 1988;75:64-66.
43. Lin TP, Murick GR. Deformities in the spores of *Nosema apis* as induced by itraconazole. *Parasitological Research* 1989;75:498-502.
44. Cox JC, Hamilton RC, Attwood HD. An investigation of the route and progression of *Encephalitozoon cuniculi* infection in adult rabbits. *Journal of Protozoology* 1979;26:260-265.
45. Didier ES, Varner PW, Didier PJ et al. Experimental Microsporidiosis in Immunocompetent and Immunodeficient Mice and Monkeys. *Folia Parasitologica* 1994;41:1-11
46. Visvesvara GS, Leitch GJ, Da silva AG, Croppo GP, Moura H, Wallace S. Polyclonal and Monoclonal antibody and PCR-amplified small sub-unit rRNA identification of microsporidia; *Encephalitozoon hellem*, isolated from an AIDS patient with disseminated infection. *Journal of Clinical Microbiology* 1994;32:2760-2768.
47. Visvesvara GS, Da silva AG, Croppo GP, Pieniazek NJ, Lietch GJ, Ferguson D. In vitro culture and serologic and molecular identification of *Septata intestinalis* isolated from urine of a patient with AIDS. *Journal of Clinical Microbiology* 1995;33:930-936.
48. Koudela B, Vitovec J, Kucerova Z, Ditrich O, Travnicek J. The severe combined immunodeficiency mouse as a Model for *Encephalitozoon cuniculi* Microsporidiosis. *Folia Parasitologica* 1993;40:279-286.